

Relationship of Renal Cortical Echogenicity in Renal Ultrasonography with Course of Disease in Children with Idiopathic Nephrotic Syndrome

Abolhassan Seyedzadeh¹, *Mohamad Reza Tohidi¹, Rahimpour Amiri^{1,2}, Nazanin Farshchian¹, Mohamad Reza Golpayegany¹, Sara Hookari¹, Mohammadsaleh Seyedzadeh¹

¹Clinical Research Development Center, Imam Reza Hospital, Kermanshah University of Medical Sciences, Kermanshah, Iran. ²Pediatric Nephrology Division, Department of Pediatrics, Hamedan University of Medical Sciences, Hamedan, Iran.

Abstract

Background

It is important to find a predictor for the course of Idiopathic Nephrotic Syndrome for better planning of treatment. Renal cortical echogenicity in ultrasonography has been postulated as a marker for the course of renal disease. The present study aimed at evaluating the relationship between renal cortical echogenicity and the course of Idiopathic Nephrotic Syndrome in children.

Materials and Methods: In this cross-sectional study, the samples were consisted of 42 patients under 17 years old with Idiopathic Nephrotic Syndrome, who was admitted to Imam Reza Hospital, Kermanshah city, Iran, during 2015–2016. The echogenicity of renal cortex and liver was compared using the sonography scanning, and divided into three grades; grade (0): echogenicity of the renal cortex less than that of the liver, grade (1): echogenicity of the renal cortex is equal to that of the liver, and grade (2): The renal cortical echogenicity is greater than that of the liver.

Results: Twenty-five patients (59.5%) were male and 17 patients (40.5%) were female. Twenty-seven patients (64.2%) were steroid-responsive, 10 patients (23.8%) were steroid-dependent and five patients (11.9%) were steroid-resistant. There was no statistically significant relationship between genders and the steroid response ($p=0.81$), but there was a statistically significant relationship between the course of the disease and the renal cortical echogenicity ($p=0.01$).

Conclusion

The results showed a relationship between steroid response and the course of the disease with renal cortex echogenicity, which means that higher renal cortical echogenicity may be a predictor of a more complicated course in Idiopathic Nephrotic Syndrome. Moreover, the small sample size, especially in the steroid-resistant group, was a limitation in the present study.

Key Words: Children, Nephrotic Syndrome, Nephrotic Syndrome, Renal Cortex Echogenicity.

*Please cite this article as: Seyedzadeh A, Tohidi MR, Amiri R, Farshchian N, Golpayegany MR, Hookari S, et al. Relationship of Renal Cortical Echogenicity in Renal Ultrasonography with Course of Disease in Children with Idiopathic Nephrotic Syndrome. *Int J Pediatr* 2020; 8(7): 11673-680. DOI: 10.22038/ijp.2020.49274.3941

*Corresponding Author:

Mohammadreza Tohidi, MD, Department of Pediatrics, School of Medicine, Clinical Research Development Center, Imam Reza Hospital, Kermanshah University of Medical Sciences, Kermanshah, Iran. Fax: +98-9177135106

Email: Tohidimohamadreza@yahoo.com

Received date: Apr.11, 2020; Accepted date: Jun.22, 2020

1- INTRODUCTION

Nephrotic Syndrome (NS) is defined as an association of edema, hypoalbuminemia, proteinuria in the nephrotic range (proteinuria $\geq 50\text{mg/kg/day}$ or 40mg/h/m^2), and hyperlipidemia (1). The common pathophysiological characteristic of NS is an abnormal passage of protein, at the level of the glomerular filtration barrier, which leads to massive protein leakage. The treatment should be commenced early to reduce hypoproteinemia and its secondary effects. Usually, pediatric NS responded to a course of treatment with steroids (steroid-responsive). However, some cases are resistant to steroid (steroid-resistant) (2, 3).

Ultrasonography (US) is a major diagnostic tool for assessment of the urinary tract in children. In sonograms, the renal usually shows a corticomedullary differentiation, with the cortex being relatively more echogenic compared to the medulla (4, 5). According to the sonography, hyper-echogenicity of the cortex is determined through comparison with the echogenicity of the liver. This comparison and grading of increased echogenicity are usually carried out subjectively, but quantitative echogenicity measurements have also been proposed (6). Increased renal echogenicity is a non-specific but significant sonographic finding, which suggests various underlying renal abnormalities (7). Furthermore, rare studies have been carried out on the contribution of the US to the differential diagnosis of NS, in which the contribution of the US is described as non-specific (7, 8). Current sonographic equipment allows the identification of three anatomic regions in the normal renal parenchyma; the cortex, which produces homogeneous, back-scattered echoes; the medulla or pyramids, which are less echogenic; and the arcuate vessels, which are seen at the corticomedullary junction as specular echoes (9). The contribution of the US in

the diagnosis of Nephrotic Syndrome has rarely been described (10). However, the prognostic significance of these abnormalities is unclear. Therefore, we evaluated the relationship between sonographic findings at presentation, and the eventual outcome in terms of steroid-responsiveness, steroid-dependency/frequently relapsing, and steroid-resistance in pediatric patients with Nephrotic Syndrome. Since identifying the factors affecting the progression and prognosis of patients with Idiopathic Nephrotic Syndrome is very helpful in making the right treatment decisions, the present study aimed at investigating the relationship between renal cortical echogenicity in renal ultrasonography, with a course of diseases in children with Idiopathic Nephrotic Syndrome.

2- MATERIALS AND METHODS

2-1. Study design and population

In this cross-sectional study, the sample population consisted of patients under 17 years old with Idiopathic Nephrotic Syndrome, who was admitted to Imam Reza Hospital, Kermanshah city, Iran, during 2015 to 2016 were enrolled and followed up between 1-4 year (median of follow up' time =2 year). The exclusion criteria were Congenital Nephrotic Syndrome, Secondary Nephrotic Syndrome, patients less than 12 months old, patients treated with non-steroid drugs, and patients with other renal disorders that cause an increase of echogenicity and patients with liver disease. Sampling was performed by available method in the relevant time period. Routine examinations and US imaging of the renal cortex and liver was carried out at the presentation of the disease. Renal cortex and liver echogenicity were compared. Since in normal patients, the renal cortex is less echogenic compared to the liver, we compared the echogenicity of the renal

cortex and the liver and graded in the following manner; grade (0): echogenicity of the renal cortex less than that of the liver; grade (1): echogenicity of the renal cortex is equal to that of the liver, and grade (2): echogenicity of the renal cortex is greater than that of the liver (11). All patients were treated with 60 mg/m^2 of prednisone for four weeks (maximum prednisolone dose 80 mg/day). The prednisone dose was tapered to $40 \text{ mg/m}^2 / \text{day}$ given every other day as a single daily dose for at least four weeks. Afterward, the alternate-day dose was tapered slowly. Children with whom the proteinuria lasted in them (2+ or greater) after four weeks of steroid therapy were considered steroid-resistant. A subset of patient relapses while on alternate-day steroid therapy, or within 14 days of completing a successful course of prednisone therapy was considered steroid-dependent and patients with four or more relapses during one year were considered as frequent relapser. Sonography imaging of the renal cortex and liver was performed in the first week of admission before start treatment for all patients, by an expert pediatric sonographer. After the start of treatment, the course of the disease and the type of response to prednisolone in patients were closely monitored and finally adapted to the cortical echogenicity of the kidney in the initial ultrasound to determine the results of the study.

2-2. Ethical consideration

Human rights were respected based on the Helsinki Declaration 1975, as revised in 1983. The ethical committee of Iran

University of Medical Sciences (Ethical code; IR.KUMS.REC. 1394.51) approved the study. The informed consent was taken from the patients, their parents, and their first relatives. Additionally, this paper was extracted from the residential thesis of pediatric nephrology by Abolhassan Seyedzadeh with the ID-number of 94327 in Kermanshah University of Medical Sciences.

2-3. Data Analysis

The variables were classified according to the frequency and the percentage. The average and standard deviation (with maximum and minimum values) were used for continuous quantitative variables. Comparisons of classified variables were carried out using Chi-square testing or Fisher's exact test. Statistical analysis was performed using SPSS Version 16.0 (SPSS, Chicago, IL). $P < 0.05$ was considered significant.

3- RESULTS

Patients with Nephrotic Syndrome who were admitted to Imam Reza Hospital during 2015-2016, were enrolled ($n=42$) and followed up between 1-4 years (median of follow up' time =2 year). 25 patients (59.5%) were male and 17 patients (40.5%) were female. The age of them was less than 17 years. 27 of the patients (64.2%) were steroid-responsive. 10 patients (23.8%) were steroid-dependent/frequently relapse, and five patients (11.9%) were steroid-resistant. Moreover, 20 patients (47.62%) had renal cortical echogenicity grade 0, 16 (38.09%) grade 1, and 6 (14.29%) grade 2 (**Table.1**).

Table-1: Frequency distribution of genders, disease type and renal cortex echogenicity in patients

Variables		Number (%)
Gender	Male	25(59.5)
	Female	17(40.5)
Disease type	Steroid-Sensitive	27(64.2)
	Steroid- Dependent	10(23.8)
	Steroid-Resistant	5(11.9)
Renal Cortex	Grade 0	20(47.62)

Echogenicity	Grade I	16(38.09)
	Grade II	6(14.29)
	Total	42(100)

Most of the patients with Steroid-Sensitive had renal cortical echogenicity with grade 0. In other words, 17(40.47%) patients with Steroid-Sensitive had renal cortical echogenicity grade 0, 9 (21.4%) grade 1, and only 1 (2.38%) grade II. On the other hand, all the patients with steroid-resistant

had to increase renal cortical echogenicity, 2(4.76%) in grade1, and 3 (7.14%) grade 2. However, in steroid-dependent patients, 3 (7.14%) were renal cortical echogenicity with grade 0. Additionally 5 (11.9%) were in grade 1 and 2 (4.76%) were in grade 2 (**Table. 2, Figure.1**).

Table-2: Frequency distribution of renal cortex echogenicity and disease type.

Variables	Disease type				
	Num(%)				
	Steroid-Sensitive	Steroid- Dependent	Steroid-Resistant	Total	
Renal Cortex Echogenicity	Grade 0	17(40.47)	3(7.14)	0(0.0)	20(47.62)
	Grade I	9(21.4)	5(11.9)	2(4.76)	16(38.09)
	Grade II	1(2.38)	2(4.76)	3(7.14)	6(14.29)
	Total	27(64.28)	10(23.8)	5(11.9)	42(100)

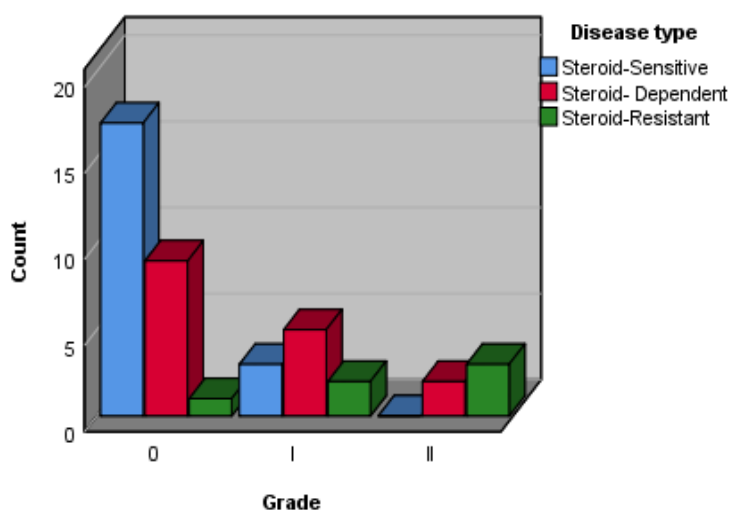


Fig.1: Chart for frequency distribution of renal cortex echogenicity and disease type.

The steroid-resistant group consisted of three males and females. In the steroid-dependent group, seven males and three females participated in the study. Likewise, seventeen males and ten females were also in the steroid-sensitive group. Considering the small number of patients in this group, we merged steroid-resistant and steroid-dependent/frequently relapses

groups together to evaluate the relationship between sexes with the outcome of steroid response (**Table.3**). According to the **Table. 3** there was no significant statistical relationship between gender and INS outcome (p=0.81). Likewise, because of the small number of patients, we merged steroid-resistant and steroid-dependent/frequently relapser groups and renal

cortical echogenicity grades I and II together to evaluate the relationship between the course of the disease and renal cortical echogenicity (**Table.4**). **Table.4**

reveals a statistically significant relationship between renal cortical echogenicity with the outcome of steroid response ($p = 0.01$) (**Figure.2**).

Table-3: Association between gender and outcome of steroid response.

Variable	Outcome of Steroid Response		P-value
	Num(%)		
	Steroid-Sensitive	Steroid-Dependent and Resistant	
Gender	Male	17(40.47)	10(23.8)
	Female	10(23.8)	5(11.9)
	Total	27(64.2)	15(35.71)

Table-4: Association between renal cortex echogenicity with outcome of steroid response.

Variable	Outcome of Steroid Response		P-value
	Num(%)		
	Steroid-Sensitive	Steroid-Dependent and Resistant	
Renal cortex Echogenicity	Grade 0	17(40.47)	3(7.1)
	Grade I, II	10(23.8)	12(28.57)
	Total	27(64.28)	15(35.71)

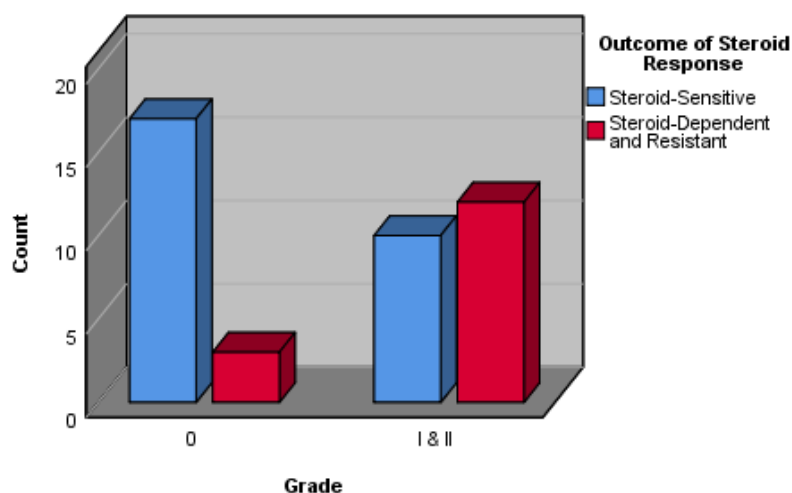


Fig.2: Chart for frequency distribution of renal cortex echogenicity and outcome of steroid response.

4- DISCUSSION

The application of parameters to predict the prognosis and clinical course of INS may change therapeutic modalities (2, 12). Unfortunately, there is restricted success in correlating the clinical course of INS with clinical and laboratory characteristics at the onset of disease.

Some equivocal predictors, which have been proven so far include low age at the onset of disease, frequent relapses during the first six months of disease, no prednisolone responsiveness in the first month of initial treatment, and low birth weight. Therefore, the evaluation of some other factors that aggravated the course of

INS is very valuable (12). The purpose of the present study was to present the renal cortical echogenicity as a predictor of INS, and we found an important relationship between renal cortical echogenicity and clinical course of INS. Increased echogenicity of renal parenchyma is an important sonographic finding. It has been shown that increased renal echogenicity is a sign of renal parenchymal (4-13). However, hyperechogenicity is not a specific finding because there is not a documented correlation between renal sonographic appearance and the renal pathology (13). The pathologic cause of increased echogenicity is often unclear, perhaps complex, and may involve glomerular, tubular, interstitial, or vascular abnormalities (14). Many renal disorders can cause an abnormal increase in renal parenchymal echogenicity. Sonographic findings in patients with Nephrotic Syndrome can show renal enlargement and a non-specific increase in renal parenchymal echogenicity.

The renal ultrasonographic appearance of the patients with glomerulonephritis may be variable, regardless of the cause of the disease. The renal ultrasonography in glycogen storage diseases shows renal enlargement, also increased cortical echogenicity (15). In the early course of Hemolytic Uremic Syndrome, the sonographic findings may be normal, or the only nephromegaly can be seen. By progressing the disease, the ultrasonography demonstrated an increased renal cortical echogenicity (15). The hyper-echogenicity is probably related to swelling of glomerular endothelial and mesangial cells and the presence of platelet aggregates and fibrin thrombi in the Lumina of glomerular capillaries (16). The ultrasonography is a popular tool, used for the work-up of patients with urinary tract infections and an effective screening modality (17). Beldek Asap et al. evaluated 144 children with acute renal

disease retrospectively (4). They assessed the correlation of clinical and laboratory findings with increased renal cortical echogenicity in children with acute renal diseases. They concluded that glomerulonephritis is the most frequent acute disease causing increased renal echogenicity in childhood, and higher echogenicity is more likely associated with hematuria. Paivansalo et al. (18) evaluated the relationship of US findings with the renal parenchymal disease in 112 patients. They showed that Nephrotic Syndrome increases the number of abnormal sonographic findings. No specific sonography features could be established for either glomerular or tubulointerstitial renal diseases. In this study, we compared the echogenicity of the renal cortex and liver in 42 patients with Nephrotic Syndrome using sonography. Afterward, we evaluated the correlation between the renal cortex with the course of disease and response to steroid therapy.

We observed a statistically significant relationship between renal cortical echogenicity and the course of Idiopathic Nephrotic Syndrome after a combination of groups (steroid-dependent /frequently relapse group and steroid-resistant group) to achieve more patients in some groups for accurate statistical analysis. The small sample size compelled us to do this manipulation and may affect our results. However, our results support the probable role of renal cortical echogenicity as a predictor of the course of Idiopathic Nephrotic Syndrome. According to our findings, increased echogenicity of the renal cortex may be a predictor of the complicated course of pediatric NS. Further investigation with larger sample size is recommended.

4-1. Limitations of the study

Because of the small sample size in the steroid-resistant group, we merged this group of patients with steroid-dependent/frequent relapsers group for

better statistical analysis. This can affect our results, especially in steroid-resistant patients.

5- CONCLUSION

The results showed the association between renal cortical echogenicity and the outcome of INS. This means that higher renal cortical echogenicity may be a predictor of a more complicated course of INS, which raises the need for more detailed follow-up by nephrologists.

6- AUTHORS' CONTRIBUTION

AS and MT designed the study, observed accuracy and validity of the study. NF had to perform ultrasound. RA and MS collected the data and follow the study. SA did the statistical analysis of the data and interpreted it. MG and AS supervised the project. RA and MT wrote the paper. All authors edited and revised the final manuscript and accepted its publication.

7- FUNDING/SUPPORT

This article is the result of the findings of the research project 94327 did what approved and financed by Vice Chancellor for Research and Technology, Kermanshah Uuniversity of Medical Sciences, Kermanshah, Iran.

8- CONFLICT OF INTEREST: None.

9- REFERENCES

1. Avni FE, Vandenhoute K, Devriendt A, Ismaili KH, Hackx M, Janssen F, et al. Update on congenital nephrotic syndromes and the contribution of US. *Pediatr Radiol*. 2011;41(1):76–81. doi:10.1007/s00247-010-1793-5.
2. Jalanko H. Congenital nephrotic syndrome. *Pediatr Nephrol*. 2009;24(11):2121–8. doi: 10.1007/s00467-007-0633-9.
3. Niaudet P, Gubler MC. WT1 and glomerular diseases. *Pediatr Nephrol*.

2006;21(11):1653–1660. doi:10.1007/s00467-006-0208-1.

4. Kasap B, Soylu A, Türkmen M, Kavukcu S. Relationship of increased renal cortical echogenicity with clinical and laboratory findings in pediatric renal disease. *J Clin Ultrasound*. 2006;34(7):339-42. doi:10.1002/jcu.20243.
5. Manley JA, O'Neill WC. How echogenic is echogenic? Quantitative acoustics of the renal cortex. *Am J Kidney Dis*. 2001;37(4):706-11. doi: 10.1016/s0272-6386(01)80118-9.
6. Northrup M, Mendez-Castillo A, Brown JC, Frazier S, Luger AM. Congenital nephrotic syndrome, Finnish type: sonographic appearance and pathologic correlation. *J Ultrasound Med*. 2003;22(10):1097–9. doi:10.7863/jum.2003.22.10.1097.
7. Avni EF. Update in pediatric renal sonography: focus on hyperechoic kidneys. *Pediatr Radiol*. 2011;41(1):94–5. doi: 10.1007/s00247-011-2040-4.
8. Salame H, Damry N, Vandenhout K, Hall M, Avni FE. The contribution of ultrasound for the differential diagnosis of congenital and infantile nephrotic syndrome. *Eur Radiol*. 2003;13(12):2674–9. doi:10.1007/s00330-003-1920-x.
9. Rosenfield AT, Taylor KJ, Crade M, DeGraaf CS. Anatomy and Pathology of the Kidney by Gray Scale Ultrasound. *Radiol*. 1978;128(3):737-44. doi:10.1148/128.3.737.
10. De La Roque C, Prezelin-Reydit M, Vermorel A, Lepreux S, Deminière C, Combe C. Idiopathic Nephrotic Syndrome: Characteristics and Identification of Prognostic Factors. *J. Clin. Med*. 2018 ;7(265); doi:10.3390.
11. Lee J, Hyun Cho M, Chung S, Dug Lim S, Sun Kim K. Relationship of Renal Echogenicity with Renal Pathology and Function. *Child Kidney Dis* 2017;21:47-52; doi: https://doi.org/10.3339/jkspn.2017.21.2.47.
12. Rezavand N, Seyedzadeh A, Tohidi MR, Seyedzadeh MS, Hookary S, Abdi A. The relationship between low-birth weight and

nephrotic syndrome in children. *J Nephropharmacol.* 2018; 7(1): 6–9.

13. Riccabona M, Mache CJ, Dell'Acqua A, et al. Renal parenchymal disease. In: Footer R. *Pediatric uroradiology*; 2001.
15. Graif M, Shohet I, Strauss S, Yahav J, Itzchak Y. Hemolytic uremic syndrome: sonographic-clinical correlation. *J Ultrasound Med.* 1984;3(12):563–4.
16. Choyke PL, Grant EG, Hoffer FA, Tina L, Korec S. Cortical echogenicity in the hemolytic uremic syndrome: clinical correlation. *J Ultrasound Med.* 1988;7(8):439-42.
14. Hayden CK Jr, Santa-Cruz FR, Amparo EG, Brouhard B, Swischuk LE, Ahrendt DK. Ultrasonographic evaluation of the renal parenchyma in infancy and childhood. *Radiology.* 1984;152(2):413-7. doi:10.1148/radiology.152.2.6739808.
17. Sty JR, Wells RG, Starshah RJ, Schroed BA. Imaging in acute renal infection in children. *Am J Roentgenol.* 1987;148(3):471-7. doi:10.2214/ajr.148.3.471.
18. Päivänsalo M, Huttunen K, Suramo I. Ultrasonographic Findings in Renal Parenchymal Diseases. *J Urol Nephrol.* 1985; 19(2):119-23.