

Chronic Myeloid Leukemia in a Young Man with Unusual Presentation of Weight Loss, Bone Pain, and Abdominal Pain

Niloufar Mohamadian¹, Mehdi Seyedmoradi¹, Babak Izadi², Farhad Amirian², Mazaher Ramezani^{2,3*}

1

1. Young Researchers and Elite Club, Kermanshah Branch, Islamic Azad University, Kermanshah, Iran

2. Molecular Pathology Research Center, Imam Reza Hospital, Kermanshah University of Medical Sciences, Kermanshah, Iran

3. Clinical Research Development Center, Imam Reza Hospital, Kermanshah University of Medical Sciences, Kermanshah, Iran

*Corresponding author: Mazaher Ramezani; Molecular Pathology Research Center, Imam Reza Hospital, Kermanshah University of Medical Sciences, Kermanshah, Iran

Email: mazaher_ramezani@yahoo.com

ABSTRACT

Chronic myeloid leukemia (CML) is a clonal myeloproliferative neoplasm and one of the main subtypes of leukemia that mainly affects adults. The incidence of CML increases slowly with age until the middle of the fourth decade, and then it rises rapidly. Anemia, splenomegaly, and constitutional symptoms are the most common signs and symptoms at presentation. Here we report a 27-year-old man with bone pain and generalized abdominal pain. He also had weight loss because of anorexia and easy satiety. The qualitative probe-based real-time PCR (qRT-PCR) result was positive for BCR-ABL1 (t9:22) P210 mutation. The patient was treated with Imatinib, the standard first-line treatment for CML, and showed clinical improvement. His pain also decreased, and he was discharged in good condition.

Keywords: Bone pain; Chronic Myeloid Leukemia; CML; Weight loss

INTRODUCTION:

Leukemia refers to a broad group of hematologic disorders that affect the blood and bone marrow and usually begins in the bone marrow. Over time, the leukemia cells develop and become a predominant clonal proliferation, then the development of normal cells is being suppressed. Leukemia can be classified based on the progress rate of leukemia cells and how they replace with the normal blood and bone marrow cells, as either acute or chronic and based on the predominant type of cells involved, as myeloid or lymphoid.^{1,2} One of the four main subtypes of leukemia is chronic myeloid leukemia (CML), also called chronic myelogenous leukemia, chronic myelocytic leukemia, and chronic granulocytic leukemia. CML is a clonal BCR-ABL1-positive myeloproliferative neoplasm (MPN) defined by the presence of the Philadelphia (Ph) chromosome in the bone marrow cells of patients (in 90% to 95% of cases). It occurs in all age groups (with the median age of 67 years), but adults under 50 are mainly affected (approximately 84%).²⁻⁶ The incidence of CML (1-2 cases per 100,000 adults) increases with age. CML accounts for 15% to 20% of all adult leukemia subtypes.³⁻⁶ Splenomegaly, a common sign of CML, and anemia result in the most common symptoms.^{2,3} Bone involvement and destructive bone changes are known features of AML and ALL, but unlike in CML, they are rarely found. Localized bone pain or joint pain occurs in some patients with CML.⁵⁻⁷

Case presentation

The patient was a 27-year-old man with bone pain, generalized abdominal pain, and weight loss. In complete blood count (CBC), white blood cells were elevated. Lab data was WBC=216x10³/μl (Reference value: 4.0-10x10³/μl), RBC=3.5x10⁶/μl (Reference value: 4.5-6.3x10⁶/μl), Hemoglobin=10.9g/dl (Reference value: 14-18 g/dl), and Platelet=168x10³/μl (Reference value: 140-440x10³/μl). Ultrasound examination revealed grade I fatty liver, spleen greater than normal (180 mm), and some Para-aortic lymph nodes measured 19x8mm. Bone marrow aspiration and trephine

biopsy were done (Figure 1 and 2). The pathologist reported that hypercellular marrow (Cellularity: 90%) with a polymorphic population of hematopoietic cells and eosinophilia are suggestive of CML. Whole blood was examined by PCR. RNA was extracted by QIAGEN QIAamp RNA Mini kit. cDNA was synthesized by Invitrogen kit. Qualitative probe-based real-time PCR (qRT-PCR) was done using standard primers and confirmed two times. The test result was: positive for BCR-ABL1 (t9:22) P210 mutation.

Treatment with Imatinib was started. Other drugs in the disease course were Allopurinol, Fluconazole, Co-trimoxazole, Dexamethasone, Diphenhydramine, and Dimethicone. The patient was discharged in good condition for further follow-up and treatment. Further follow-up was not available for the pathologist.

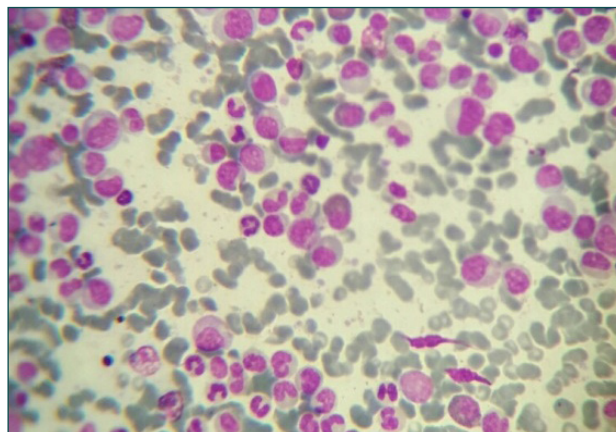


Figure.1. Bone marrow aspiration. Polymorphic population with neutrophils and eosinophils. Giemsa stain X400 magnification.

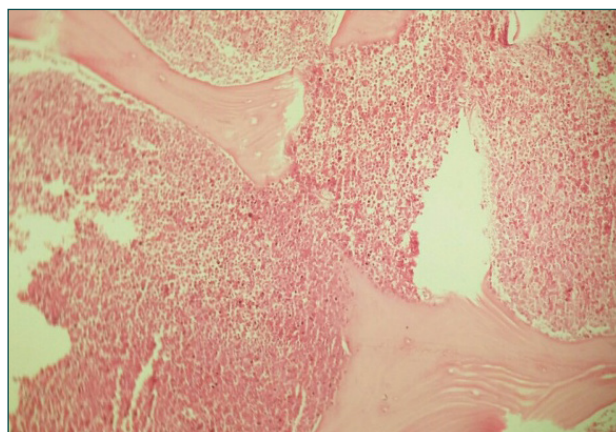


Figure.2. Bone marrow biopsy. Hypercellular marrow. Hematoxyline-Eosin stain X100 magnification.

DISCUSSION

CML develops in three different phases (chronic, accelerated, and blast phase).^{4,5} The chronic phase (CP) is the most critical phase, which can last for years and continues through an accelerated phase (AP) or blast phase (BP). If the chronic phase is not controlled and remains untreated, it causes a blast crisis resembling or completely changing into a fast-growing acute myeloid leukemia (AML) or acute lymphoid leukemia (ALL) within a period of 3 to 5 years on average.³⁻⁶ The chronic phase is present in most patients (85% to 90%),^{5,6} and CML is usually diagnosed in this phase in the developed countries.⁴

Most cases of CML occur in adults between ages 25 to 60-years. It is still scarce in children (About 2% of leukemia in children).^{1,6} The incidence of CML is higher in males than females (2.0 vs. 1.2) and increases slowly with age until the middle of the fourth decade, and then it rises rapidly.⁶ Unlike most of the previous reports and studies from other countries, we found that the age of our patient was lower than the median age at diagnosis.^{6,7} But in one of the recent studies from Saudi Arabia, which, like Iran, is an Asian country and geographically very close to Iran, approximately 35.7% of patients (20 patients) were between 21 to 40 years with a median age of 29 (Mean±SD: 29.0±6.4) which is very close to our patient's age.⁵

About 20% of patients diagnosed with CML are asymptomatic.² Splenomegaly and anemia mostly appear in the chronic phase of CML and could include weakness, fatigue, malaise, weight loss, fever, night sweats, bone pain, an enlarged spleen (felt as a mass with pain under the left side of the ribcage), abdominal pain or anorexia and a sense of fullness in the belly (in the left upper side of the ribcage), and feeling full or easy satiety, even after eating a small amount of food.^{3,5,6} However, it is noteworthy that these symptoms can occur with other leukemia as well as many non-leukemia conditions.⁶ Constitutional symptoms, such as bleeding and bruising are AML, and ALL's common presenting features, not CML's, and occur in approximately one-third of patients with CML.²

Bone pain is present, followed by bone inflammation involving the ends of long bones, the spine, skull, and pelvis.⁷ Joint pain results from a group of leukemia cells that have spread to the surface of the bone or directly into the joint, from the marrow cavity.⁶

After the initial evaluation of past medical history and physical exam to confirm the diagnosis of CML, bone marrow aspiration and biopsy for morphologic and cytogenetic evaluations and as well as qRT-PCR for molecular monitoring of BCR-ABL1 transcript levels are highly recommended.^{4,8}

The available treatment options for BCR-ABL1-positive CML include chemotherapy, immunotherapy, molecular therapy, and allogeneic stem cell transplantation (SCT). When Imatinib, one of the BCR-ABL1 tyrosine-kinase inhibitors (TKI), was approved for the treatment of CML in 2002, the treatment of CML was changed significantly.⁸⁻¹⁰ Since then, TKI therapy has been considered the first-line therapy for all patients with the newly diagnosed chronic phase of CML.^{4,5,8,9,10} TKI therapy has revolutionized the treatment of CML, and the overall survival rate and quality of life of patients with the chronic phase of CML has dramatically improved, associated with an estimated 5-year survival rate greater than 90%.^{5,6,8}

Treatment with Imatinib in some patients in the chronic phase may fail due to the intolerance or resistance, so three newer drugs with higher potency against BCR-ABL1 as the second generation of TKI treatment, Dasatinib, Nilotinib, and Bosutinib, can be used. These new drugs, alongside Imatinib, form the first-line treatment of chronic phase of CML.^{5,9,10} Although, each has shown superior efficacy than Imatinib.¹⁰

Acknowledgment

We would like to thank the Clinical Research Development Center of Imam Reza Hospital for providing consulting services.

Conflict of interest

None

REFERENCES

1. Lyengar V, Shimanovsky A (2020): Leukemia. Treasure Island (FL): StatPearls Publishing; 2020: Jan.
2. Davis AS, Viera AJ, Mead MD (2014): Leukemia: An overview for primary care. *Am Fam Physician*;89(9):731–738.
3. Jabbour E, Kantarjian H (2020): Chronic myeloid leukemia: 2020 update on diagnosis, therapy and monitoring. *Am J Hematol*;95(6):691–709.
4. Deininger MW, Shah NP, Altman JK, Berman E, Bhatia R, et al. (2020): Chronic myeloid leukemia, version 2.2021: NCCN Clinical practice guidelines in oncology. *J Natl Compr Canc Netw*;16:1108–35.
5. Algahtani FH, Alqahtany FS (2020): Evaluation and characterisation of chronic myeloid leukemia and various treatments in Saudi Arabia: A retrospective study. *J Infect Public Health*;13(2):295–8.
6. Islamiah A, Wardhani SO (2017): A 44-year-old man with chronic myeloid leukemia and mass at right lower leg. *Jurnal Kedokteran Brawijaya*; 29(4):383–6.
7. Kumar L, Baid BL, Singh Y, Kochupillai V (1991): Bone lesions in chronic granulocytic leukaemia. *Postgrad Med J*;67(790):778.
8. Kantarjian HM, Cortes J, Guilhot F, Hochhaus A, Baccarani M, Lokey L (2007): Diagnosis and management of chronic myeloid leukemia. *Cancer*; 109: 1365–1375.
9. von Bubnoff N, Duyster J (2010): Chronic myelogenous leukemia: treatment and monitoring. *Dtsch Arztebl Int*;107(7):114–121.
10. Wei G, Rafiyath S, Liu D (2010): First-line treatment for chronic myeloid leukemia: dasatinib, nilotinib, or Imatinib. *J Hematol Oncol*;3:47.