

CASE REPORT

New-onset pemphigus foliaceus following SARS-CoV-2 infection and unmasking multiple sclerosis: A case report

Fatemeh Mohaghegh¹  | Parvaneh Hatami²  | Arezoo Refaghat³ |
Mohammadjavad Mehdizadeh⁴ | Zeinab Aryanian^{2,5} | Nessa Aghazadeh Mohandesi⁶ |
Zeinab Mohseni Afshar⁷

¹Department of Dermatology, Skin Diseases and Leishmaniasis Research Center, Isfahan University of Medical Sciences, Isfahan, Iran

²Autoimmune Bullous Diseases Research Center, Tehran University of Medical Sciences, Tehran, Iran

³Department of Dermatology, Isfahan University of Medical Sciences, Isfahan, Iran

⁴Radiology Department, Zahraye Marziyeh Hospital, Isfahan, Iran

⁵Department of Dermatology, Babol University of Medical Sciences, Babol, Iran

⁶Department of Dermatology, Mayo Clinic, Rochester, Minnesota, USA

⁷Clinical Research Development Center, Imam Reza Hospital, Kermanshah University of Medical Sciences, Kermanshah, Iran

Correspondence

Parvaneh Hatami and Zeinab Aryanian, Autoimmune Bullous Diseases Research Center, Razi Hospital, Tehran University of Medical Sciences, Tehran, Iran.

Emails: p_hatami2001@yahoo.com; z_aryanian@yahoo.com

Zeinab Mohseni Afshar, Clinical Research Development Center, Imam Reza Hospital, Kermanshah University of Medical Sciences, Kermanshah, Iran. Email: z_moseni2001@yahoo.com

Funding information

None

Abstract

Development of pemphigus foliaceus (PF) following SARS-CoV-2 infection has only been reported in one patient who had received Bamlanivimab and thus might be considered as a drug-induced case of PF. Here, we reported the first case of PF arising solely after COVID infection without taking any culprit drug.

KEYWORDS

COVID-19, multiple sclerosis, pemphigus, pemphigus foliaceus, rituximab, SARS-Cov-2

1 | INTRODUCTION

The coronavirus disease 2019 (COVID-19) has opened new windows to the world of infection-related dermatologic disorders. Various forms of dermatologic involvement, from a simple hypersensitivity state to critical immune-dermatologic disorders, have arisen in the COVID pandemic.¹ The cutaneous involvement have been either new-onset or exacerbation of the preexisting dermatosis.^{2,3} Moreover, skin lesions have

been the initial manifestation of infection with the severe acute respiratory syndrome coronavirus 2 (SARS-CoV-2) or the consequence of the recent infection and its treatment.^{4,5}

Up to the present time, several cases of pemphigus vulgaris (PV) and bullous pemphigoid have been reported following SARS-CoV-2 infection^{6,7}; however, to our knowledge, our patient has been the first cases of pemphigus foliaceus (PF) and multiple sclerosis (MS) arising after COVID infection.

This is an open access article under the terms of the [Creative Commons Attribution-NonCommercial-NoDerivs](https://creativecommons.org/licenses/by-nc-nd/4.0/) License, which permits use and distribution in any medium, provided the original work is properly cited, the use is non-commercial and no modifications or adaptations are made.

© 2022 The Authors. *Clinical Case Reports* published by John Wiley & Sons Ltd.

2 | CASE PRESENTATION

A 56-year-old female presented to the dermatologic clinic with generalized bullous eruptions. She mentioned that her skin lesions had initiated one month earlier with scalp scaling, which progressed to erythema over the trunk and gradual progression to diffuse flaccid blister formation. She also reported a history of coryza, anosmia, and general weakness one week prior to her cutaneous manifestations in her family and also herself, which had subsided without treatment. Her past medical history was significant for a mild asthma, migraine, and lumbar disc surgery. She mentioned a family history of lichen planus in her cousin. Moreover, SARS-CoV-2 RT-PCR test was positive in her daughter along with COVID symptoms. She did not report any history of previous vaccination against COVID or influenza. At presentation, she had extensive nonpruritic bullous eruptions with erythematous base over the trunk. Physical examination revealed generalized skin blisters with underlying erythema and “cornflake” scaly plaques and erosions without nail, palms, and soles involvement (Figure 1).

Mucosal surfaces were also intact. Her RT-PCR test result for SARS-CoV-2 was reported negative at presentation but her lung CT scan revealed a few peripheral ground glass opacities in right upper lobe which was highly suggestive of COVID-19 pneumonia (Figure 2).

She underwent skin punch biopsy, which showed spongiotic dermatitis along with subcorneal splitting (Figure 3).

Direct immunofluorescence (DIF) microscopy also revealed intercellular deposits of IgG and C3, compatible with PF. Her laboratory data was significant for high anti-desmoglein 1 and 3 (DSG1, 3) antibody levels of 1/320 for both of them, which was also consistent for PF. She was

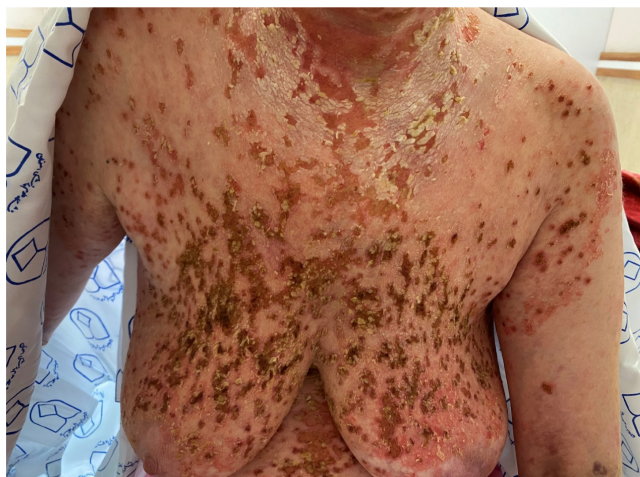

FIGURE 1 Generalized erosive lesions with underlying erythema and “cornflake” scaly plaques

started on high dose oral prednisolone and azathioprine in addition to topical corticosteroid. However, her cutaneous lesions progressed on treatment and involved the extremities; therefore, she was hospitalized to receive IVIG. Five days after admission, she developed pancytopenia, which made us request a hematologic consult. Abdominopelvic ultrasound was normal with no organomegaly. Her viral markers, including HIV, HBV, and HCV, were negative. PBS showed anisocytosis. Due to her declining hemoglobin, stool examination was performed, which turned out to be positive for occult blood. The gastroenterologist recommended a thorough GI endoscopy after hospital discharge. However, her cutaneous lesions showed favorable response after receiving IVIG. Meanwhile, she complained of a general weakness, which aggravated after admission and was followed by ataxia. Neurological consult recommended cervical Doppler ultrasound and brain CT scan, which were normal, and EMG-NCV, which demonstrated proximal myopathy. Initially, the myopathy was supposed to be the result of prolonged corticosteroid use; however, brain MRI with gadolinium, which was performed due to the deterioration of her muscular weakness, showed two hypersignal spots on T2W FLAIR sequences perpendicular to long axis of the lateral ventricle and a similar lesion in juxta cortical area of right frontal region, characteristic of demyelinating disease and MS (Figure 4).

She was started on rituximab for MS, along with azathioprine and prednisolone for PF. As her dermatologic condition improved considerably, the medications were tapered step by step.

At present, she is receiving only prednisolone on 5 mg/day and her PF lesions have been healed without developing any new lesion (Figure 5).

3 | DISCUSSION

PF is a rare subgroup of bullous skin disorders, which occurs as a result of anti-desmoglein-1 antibodies production against the intercellular adhesion DSG1 protein. There are several triggering factors for the evolution of pemphigus which include medications, vaccines, genetic predisposition, pregnancy, and stress.⁸ However, infections had rarely been known as an underlying risk factor until the COVID-19 pandemic. The SARS-CoV-2 infection has given rise to many cases of dermatoses, either new-onset or exacerbation, with pemphigus family being one of them.^{9–12} Reviewing the literature had led us to merely one case of SARS-CoV-2-related PF, which appeared after receiving Bamlanivimab.¹³ However, our case was a new-onset PF without a history of drug consumption.

Induced autoimmunity is supposed to be the underlying mechanism of new-onset or flares of dermatologic

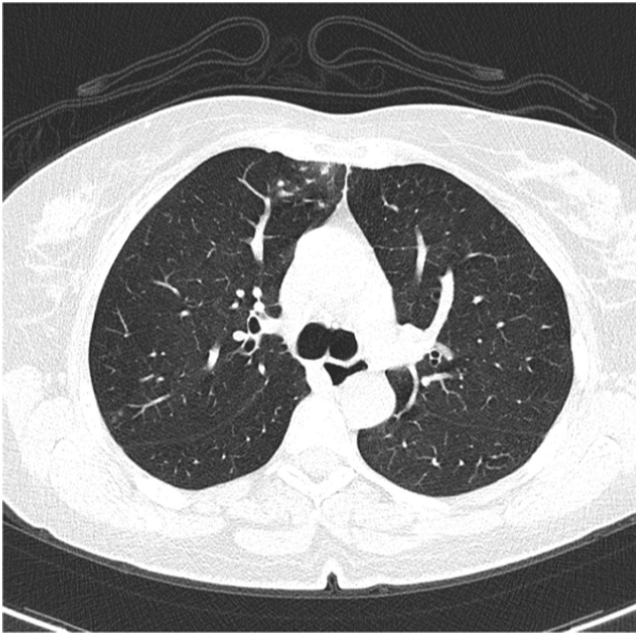


FIGURE 2 A few peripheral ground glass opacities in right upper lobe

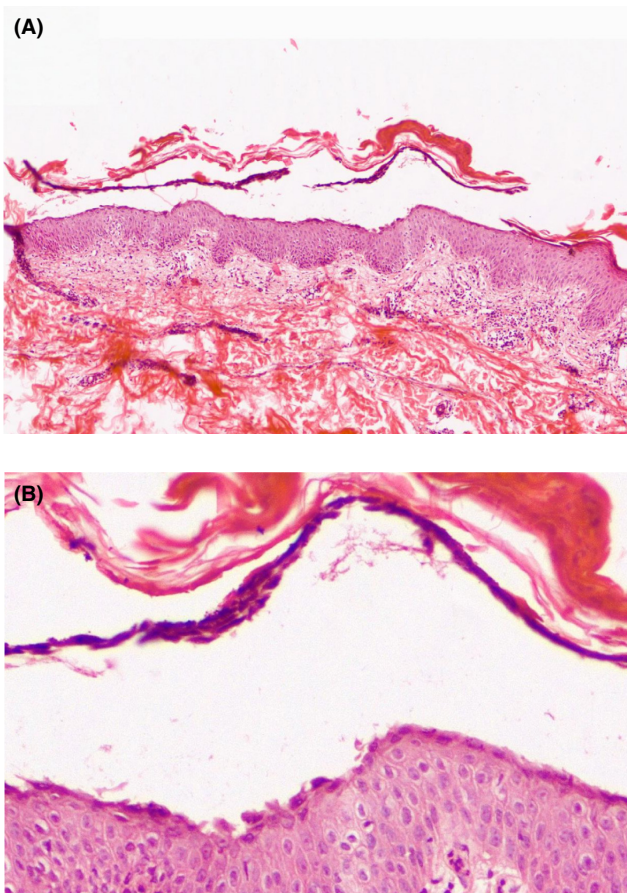


FIGURE 3 Spongiotic dermatitis along with subcorneal splitting which is compatible with diagnosis of PF (H&E $\times 40$) (A). Subcorneal splitting with acantholytic cells. (H&E $\times 100$) (B)

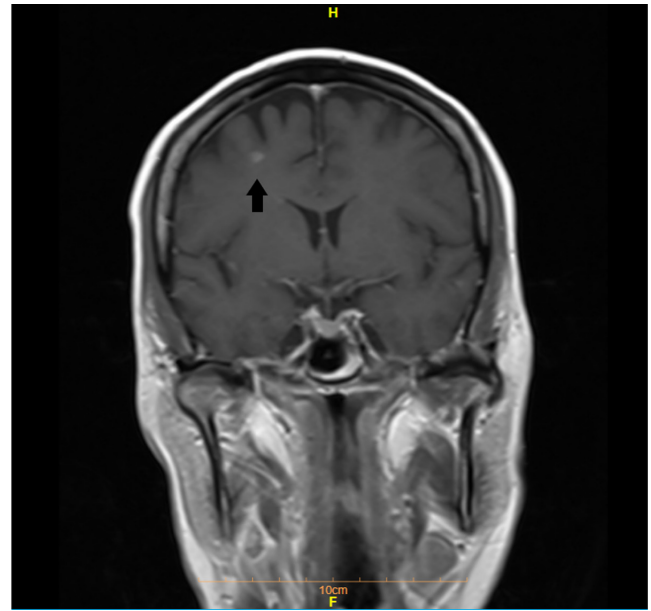


FIGURE 4 Demyelinating lesions suggestive of M.S

disorders following SARS-CoV-2 infection; molecular mimicry can lead to antibody production against self-antigens and subsequently immune-dermatologic diseases. Moreover, the SARS-CoV-2-induced immune dysregulation gives rise to hypersensitivity and consequently, cutaneous lesions.⁷

PF is classically presented with fragile loose blisters over seborrheic areas such as face, scalp, and upper trunk. The differentiating clinical characteristic of PF from PV is the mucous membrane sparing and extensive erythema in the former.¹⁴ However, demonstrating separation of keratinocytes at the granular layer of the epidermis, preacantholytic vacuole formation in intercellular spaces and subcorneal blisters in the histopathologic examination confirms the diagnosis of PF.¹⁵ DIF, demonstrating intercellular deposition of IgG and C3, and indirect immunofluorescence microscopy for detecting serum auto-antibodies against DSGs are highly sensitive and specific methods for diagnosing pemphigus, as aided us significantly for the patient.¹⁶

Systemic corticosteroids are still the mainstay and first-line treatment of pemphigus. However, in moderate-to-severe cases, oral azathioprine or a mycophenolate compound is added.¹⁷ Our patient did not respond to either of the aforementioned agents; therefore, we started her on second-line treatment, IVIG, which led to relative resolution of skin lesions.

Another important issue was the contribution of SARS-CoV-2 in triggering new onset or exacerbations of neuro-immunological disease like MS.¹⁸ This phenomenon occurred in our patient who was probably a case of

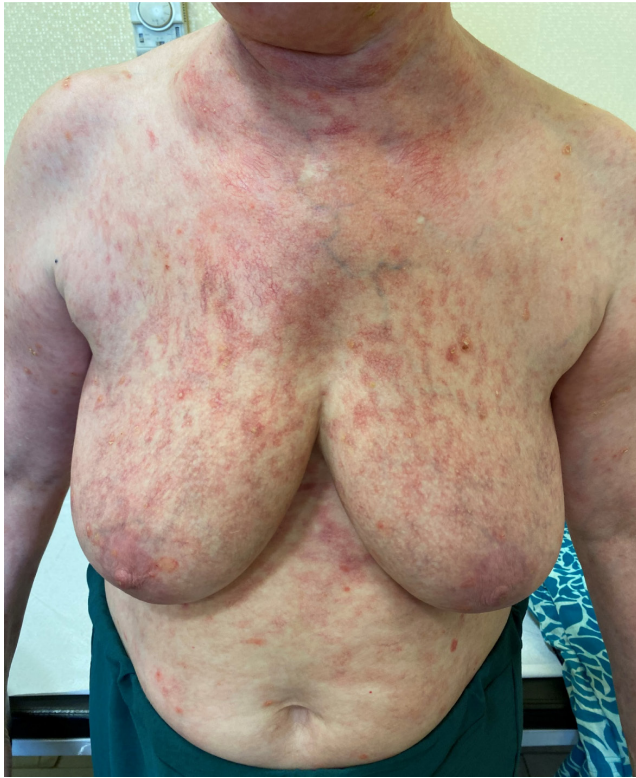

FIGURE 5 Considerable clinical remission after treatment

undiagnosed MS. The patient experienced intermittent bouts of limbs paresthesia and headache but neglected them. At admission, her muscular weakness was falsely considered as a manifestation of corticosteroid myopathy. Nevertheless, with aggravation of limbs weakness and the added ataxia, thorough neurological workup revealed an underlying MS, which relapsed with SARS-CoV-2 infection.

It is interesting to know that new guidelines focus on the administration of rituximab as the first-line treatment for pemphigus, since it leads to more cases of remission even after one cycle.^{19–22} Our patient received rituximab for her underlying neurological disorder, MS, but this had done her favor as it led to complete resolution of cutaneous eruptions.

4 | CONCLUSION

SARS-Cov-2 infection could have led to any dermatologic condition, including insignificant and critical ones. Therefore, we should take into account these entities in any patient presenting with new-onset or exacerbating cutaneous reaction.

AUTHOR CONTRIBUTIONS

All the authors listed above have equally participated in preparing the manuscript.

ACKNOWLEDGEMENT

None.

CONFLICT OF INTERESTS

The authors declare that they have no competing interests.

DATA AVAILABILITY STATEMENT

The data that support the findings of this study are available from the corresponding author, upon reasonable request.

ETHICAL APPROVAL

Ethical approval from the Medical Ethics Committee of Isfahan University of Medical Sciences was provided.

CONSENT

A written informed consent was obtained from the patient for publication of this case report and any accompanying images. A copy of the written consent is available for review by the Editor-in-Chief of this journal.

ORCID

Fatemeh Mohaghegh  <https://orcid.org/0000-0002-8492-2410>

Parvaneh Hatami  <https://orcid.org/0000-0002-3531-2907>

REFERENCES

- Mohseni Afshar Z, Babazadeh A, Hasanpour A, et al. Dermatological manifestations associated with COVID-19: A comprehensive review of the current knowledge. *J Med Virol*. 2021;93(10):5756–5767.
- Afshar ZM, Miladi R, Janbakhsh A, Babazadeh A, Aryanian Z, Ebrahimpour S. Unmasking pustular psoriasis subsequent to COVID-19. *J Pak Assoc Dermatol*. 2021;31(3):526–529.
- Miladi R, Janbakhsh A, Babazadeh A, et al. Pustular psoriasis flare-up in a patient with COVID-19. *J Cosmet Dermatol*. 2021;20(11):3364–3368.
- Kalantari Y, Sadeghzadeh-Bazargan A, Aryanian Z, Hatami P, Goodarzi A. First reported case of delayed-type hypersensitivity reaction to non-hyaluronic acid Polycaprolactone dermal filler following COVID-19 vaccination: A case report and a review of the literature. *Clin Case Rep*. 2022;10(2). doi:10.1002/ccr3.5343
- Aryanian Z, Balighi K, Hatami P, Tootoonchi N, Goodarzi A, Mohseni Afshar Z. Morphea in two patients after being infected to and being vaccinated against SARS-CoV-2 infection. *Clin Case Rep*. 2022;10(4). doi:10.1002/ccr3.5667
- Salazar-Paras DKR, Ramirez-Quizon MN. Present Tense: A Peculiar Case of Pemphigus Vulgaris Presenting with Tense Blisters during the COVID-19 Pandemic. *Acta Medica Philippina*. 2021;55(5). doi:10.47895/amp.v55i5.2890
- Presenting with Tense Blisters during the COVID-19 Pandemic. *Acta Medica Philippina*. 2021;55(5).
- De Medeiros VLS, Monteiro-Neto AU, França DDT, Castelo Branco R, de Miranda Coelho ÉO, Takano DM. Pemphigus

- vulgaris after COVID-19: a case of induced autoimmunity. *SN Comprehensive Clin Med*. 2021;3(8):1768-1772.
9. Tavakolpour S. Pemphigus trigger factors: special focus on pemphigus vulgaris and pemphigus foliaceus. *Arch Dermatol Res*. 2018;310(2):95-106.
 10. Ghalamkarpour F, Pourani MR. Aggressive course of pemphigus vulgaris following COVID-19 infection. *Dermatol Ther*. 2020.
 11. Mohaghegh F, Hatami P, Aryanian Z. A case of atypical disseminated herpes zoster in a patient with COVID-19; a diagnostic challenge in COVID era. *J Clin Case Rep*. 2022. doi:[10.1002/ccr3.5342](https://doi.org/10.1002/ccr3.5342)
 12. Hatami P, Balighi K, Nicknam Asl H, Aryanian Z. Serious health threat of mucormycosis during the ongoing COVID-19 pandemic: what dermatologists need to know in this regard. *Int J Dermatol*. 2022. doi:[10.1111/ijd.16101](https://doi.org/10.1111/ijd.16101). Epub ahead of print. PMID: 35094397.
 13. Aryanian Z, Balighi K, Hatami P, et al. Morphea in two patients after being infected to and being vaccinated against SARS-CoV-2 infection. *J Clin Case Rep*. 2022.
 14. Urban K, Giesey RL, Delost GR. Pemphigus foliaceus after COVID-19 infection and bamlanivimab infusion. *SKIN J Cutaneous Med*. 2021;5(6):660-663.
 15. Schmidt E, Kasperkiewicz M, Joly P. Pemphigus. *Lancet*. 2019;394(10201):882-894.
 16. James KA, Culton DA, Diaz LA. Diagnosis and clinical features of pemphigus foliaceus. *Dermatol Clin*. 2011;29(3):405-412.
 17. Balighi K, Ashtar Nakhaei N, Daneshpazhooh M, et al. Pemphigus patients with initial negative levels of anti-desmoglein; a subtype with different profile? *Dermatol Ther*. 2022;35:e15299.
 18. Yeh SW, Sami N, Ahmed RA. Treatment of pemphigus vulgaris. *Am J Clin Dermatol*. 2005;6(5):327-342.
 19. Finsterer J. SARS-CoV-2 triggered relapse of multiple sclerosis. *Clin Neurol Neurosurg*. 2022;215:107210.
 20. Aryanian Z, Balighi K, Daneshpazhooh M, et al. Rituximab exhibits a better safety profile when used as a first line of treatment for pemphigus vulgaris: a retrospective study. *Int Immunopharmacol*. 2021;96:107755.
 21. Balighi K, Hatami P, Sheikh Aboli MJ, et al. Multiple cycles of rituximab therapy for pemphigus: a group of patients with difficult-to-treat disease or a consequence of late rituximab initiation? *Dermatol Ther*. 2021:e15249. doi:[10.1111/dth.15249](https://doi.org/10.1111/dth.15249). Epub ahead of print. PMID: 34910350.
 22. Hatami P, Balighi K, Nicknam Asl H, Aryanian Z. COVID vaccination in patients under treatment with rituximab: a presentation of two cases from Iran and a review of the current knowledge with a specific focus on pemphigus. *Dermatol Ther*. 2022;35(1):e15216. doi:[10.1111/dth.15216](https://doi.org/10.1111/dth.15216). Epub 2021 Dec 1. PMID: 34811862.

How to cite this article: Mohaghegh F, Hatami P, Refaghat A, et al. New-onset pemphigus foliaceus following SARS-CoV-2 infection and unmasking multiple sclerosis: A case report. *Clin Case Rep*. 2022;10:e05910. doi:[10.1002/ccr3.5910](https://doi.org/10.1002/ccr3.5910)