


## REVIEW

# SARS-CoV-2-related and Covid-19 vaccine-induced thromboembolic events: A comparative review

Zeinab Mohseni Afshar<sup>1</sup> | Mohammad Barary<sup>2,3</sup>  | Arefeh Babazadeh<sup>4</sup> |  
Rezvan Hosseinzadeh<sup>2</sup> | Amirmasoud Alijanpour<sup>5</sup> | Seyed Rouhollah Miri<sup>6</sup> |  
Terence T. Sio<sup>7</sup> | Mark J. M. Sullman<sup>8,9</sup> | Kristin Carson-Chahhoud<sup>10</sup> |  
Florian Langer<sup>11</sup> | Soheil Ebrahimpour<sup>4</sup>

<sup>1</sup>Clinical Research Development Center, Imam Reza Hospital, Kermanshah University of Medical Sciences, Kermanshah, Iran

<sup>2</sup>Student Research Committee, Babol University of Medical Sciences, Babol, Iran

<sup>3</sup>Students' Scientific Research Center (SSRC), Tehran University of Medical Sciences, Tehran, Iran

<sup>4</sup>Infectious Diseases and Tropical Medicine Research Center, Health Research Institute, Babol University of Medical Sciences, Babol, Iran

<sup>5</sup>Faculty of Medicine, Semmelweis University, Budapest, Hungary

<sup>6</sup>Cancer Research Center, Cancer Institute of Iran, Tehran University of Medical Science, Tehran, Iran

<sup>7</sup>Department of Radiation Oncology, Mayo Clinic, Phoenix, Arizona, USA

<sup>8</sup>Department of Social Sciences, University of Nicosia, Nicosia, Cyprus

<sup>9</sup>Department of Life and Health Sciences, University of Nicosia, Nicosia, Cyprus

<sup>10</sup>Australian Centre for Precision Health, University of South Australia, Adelaide, Australia

<sup>11</sup>Zentrum für Onkologie, II. Medizinische Klinik und Poliklinik, Universitätsklinikum Eppendorf, Hamburg, Germany

## Correspondence

Soheil Ebrahimpour, Infectious Diseases and Tropical Medicine Research Center, Health Research Institute, Babol University of Medical Sciences, Babol, Iran.

Email: [drsoheil1503@yahoo.com](mailto:drsoheil1503@yahoo.com)

## Abstract

Since the start of the pandemic, thrombotic events have been a well-known and severe complication associated with severe acute respiratory syndrome coronavirus 2 (SARS-CoV-2) infection. Nevertheless, the initiation of vaccination programs brought another rare yet highly fatal thrombotic event, vaccine-induced immune thrombotic thrombocytopenia, which has caused extensive debate regarding the safety of vaccines. This review defines the thromboembolic events following infection and vaccination, identifies their risk factors, describes their pathophysiology, and discusses their management, treatment, and prevention.

**Abbreviations:** ACE2, angiotensin-converting enzyme 2; ACIP, Advisory Committee on Immunisation Practices; AION, anterior ischemic optic neuropathy; ARDS, acute respiratory distress syndrome; Btk, Bruton tyrosine kinase; CBC, complete blood count; CDC, Centres for Disease Control and Prevention; CLIA, chemiluminescence immunoassay; CNS, central nervous system; Covid-19, coronavirus disease 2019; CR1, complement receptor 1; CRP, C-reactive protein; CTPA, computed tomography pulmonary angiogram; CVA, cerebrovascular accidents; CVST, cerebral venous sinus thrombosis; CVVH, continuous veno-venous hemofiltration; DIC, disseminated intravascular coagulation; DOACs, direct oral anticoagulants; DVT, deep vein thrombosis; ECMO, extracorporeal membrane oxygenation; ELISA, enzyme-linked immunosorbent assay; EMA, European Medicines Agency; ESR, erythrocyte sedimentation rate; FcγRIIa, platelet FcγRIIa receptors; FEU, fibrinogen-equivalent units; FIXa, factor IXa; FXa, factor Xa; GPIIb, glycoprotein IIb; HIPA assay, heparin-induced platelet aggregation assay; HIT, heparin-induced thrombocytopenia; ICAM-1, intercellular adhesion molecule 1; ICH, intracranial haemorrhage; ICU, intensive care unit; IL-1, interleukin-1; IL-8, interleukin-8; ITP, immune thrombocytopenia; IV, intravenous; IVIG, intravenous immunoglobulin; LMWH, low-molecular-weight heparin; MAC, membrane attack complex; Mac-1, macrophage-1 antigen; MCP-1, monocyte chemoattractant protein 1; MOF, multi-organ failure; MRV, magnetic resonance venography; NET, neutrophil extracellular traps; PAI-1, plasminogen activator inhibitor-1; PBS, peripheral blood smear; PCT, procalcitonin; PE, pulmonary embolism; PF4, platelet factor 4; PRAC, Pharmacovigilance Risk Assessment Committee; PSGL-1, P-selectin glycoprotein ligand-1; PTE, pulmonary thromboembolism; PVT, pulmonary venous thrombosis; RIA, rapid immunoassay; RT-PCR, reverse-transcriptase-polymerase-chain-reaction; SARS-CoV-2, severe acute respiratory syndrome coronavirus 2; SRA, serotonin release assay; SVT, superficial venous thrombosis; TF, tissue factor; TMA, thrombotic microangiopathy; TNF-α, tumour necrosis factor-α; tPA, tissue plasminogen activator; TTS, thrombosis with thrombocytopenia syndrome; UFH, unfractionated heparin; VIT, vaccine-induced thrombocytopenia; VITT, vaccine-induced immune thrombotic thrombocytopenia; VKAs, vitamin K antagonists; V/Q scan, pulmonary ventilation/perfusion scan; VTE, venous thromboembolism; vWF, Von Willebrand factor.

**KEYWORDS**

Covid-19, SARS-CoV-2, thrombosis, VITT

## 1 | INTRODUCTION

The coronavirus disease 2019 (Covid-19) has various presentations, from a flu-like illness to acute respiratory distress syndrome (ARDS), multi-organ failure, and death.<sup>1,2</sup> Thrombotic events are a well-known severe complication of severe acute respiratory syndrome coronavirus 2 (SARS-CoV-2) infection. Following the introduction of Covid-19 vaccines, the morbidity and mortality associated with infection-induced thromboembolic events were expected to decrease significantly.<sup>3</sup> However, thromboembolic events have also become a significant concern following vaccination, especially with adenoviral vector vaccines,<sup>4</sup> which have raised several debatable questions and challenges. This article discusses the similarities and differences between SARS-CoV-2-induced and Covid-19 vaccine-induced thrombosis.

## 2 | DEFINITION AND INCIDENCE

### 2.1 | SARS-CoV-2-related thrombosis

The coronavirus disease 2019 has been related to systemic coagulopathy and thromboembolic events.<sup>5</sup> The incidence of these complications depends on the setting within which they occur and the vessels involved. For example, a study estimated the incidence of pulmonary embolism (PE) and deep vein thrombosis (DVT) to be 13.5% and 11.8%, respectively.<sup>6</sup>

### 2.2 | The coronavirus disease 2019 vaccine-related thrombosis

Since the beginning of the Covid-19 vaccination programs, several cases of thromboembolic events have been reported, specifically, from the European Medicines Agency's (EMA) Pharmacovigilance Risk Assessment Committee (PRAC) update: over 1000 events related to thrombosis from vaccines have been reported worldwide up to 31 July 2021.<sup>7</sup> Thrombosis with thrombocytopaenia syndrome, also known as vaccine-induced immune thrombotic thrombocytopenia (VITT), has been more commonly reported following adenoviral vector vaccines, such as the ChAdOx1 nCoV-19 (Oxford-AstraZeneca) and AD26.COV2.S (Johnson & Johnson/Janssen) vaccines, with the latter having the lower number of reported VITT cases of two, which is likely due to the fact that the AstraZeneca vaccine is more commonly used than the Johnson & Johnson/Janssen vaccine, as the first one has been approved in 10 times as many countries as the latter.<sup>8</sup> Moreover, some suspected VITT cases had been observed following vaccination with mRNA vaccines, all of which were

associated with the mRNA-1273 (Moderna) vaccine.<sup>9,10</sup> Despite the very low incidence of VITT after administration of the vaccines mentioned above, the high rate of vaccinations globally has resulted in a relatively high number of VITT cases.<sup>11</sup> Nevertheless, since the overall incidence of thromboembolic events is rare and the overall benefits outweigh the potential side effects, the Centres for Disease Control and Prevention and the Advisory Committee on Immunisation Practices continue to recommend the ChAdOx1 nCoV-19 and AD26.COV2.S vaccines for adults.<sup>12</sup>

Not all thromboembolic events following anti-SARS-CoV-2 vaccination are necessarily VITT, as VITT has some specific features, such as severe, persistent, or recurrent headaches, abdominal pain, shortness of breath, chest pain, limb pain or swelling, sometimes accompanied by a flu-like syndrome, occurring 4–30 days after vaccination. Also, arterial or venous thrombosis, thrombocytopenia (symptoms may include petechial or mucosal bleeding), positive antiplatelet factor 4 (PF4)/polyanion antibodies, and a positive platelet activation assay (e.g., serotonin release assay (SRA)) would be present in this condition.<sup>13</sup>

In a study by Scully et al.<sup>14</sup> 22 patients with no history of prothrombotic conditions (all received the first dose of the ChAdOx1 nCoV-19 vaccine 6–24 days before presentation) presented with acute thrombocytopenia and thrombosis, primarily cerebral venous sinus thrombosis (CVST), and 1 patient presented with isolated thrombocytopenia and a hemorrhagic phenotype. All the patients had low or normal fibrinogen levels and elevated D-dimer levels at presentation. Moreover, most patients tested positive for anti-PF4/polyanion antibodies, with only one tested negative. Treatment with non-heparin anticoagulants and intravenous immunoglobulin (IVIG) is warranted. Furthermore, platelet transfusions should be avoided because of the risk of progression in thrombotic symptoms.<sup>14</sup>

## 3 | RISK FACTORS

### 3.1 | SARS-CoV-2-related thrombosis

The risk factors of thromboembolic events in a Covid-19 patient are primarily the same as the Virchow triad: endothelial cell dysfunction or inflammation, blood flow stasis, and hypercoagulability. The underlying mechanisms consist of (1) increased levels of pro-inflammatory cytokines, leading to a high-grade inflammatory state in these patients<sup>15</sup>; (2) high expression of angiotensin-converting enzyme 2 (ACE2) on the endothelial cell membrane, acting as the entry point for SARS-CoV-2 into the cells<sup>16</sup>; and (3) immobilisation imposed by prolonged hospitalisation, or paralysis-induced by the disease itself.<sup>17,18</sup> Moreover, Covid-19 patients who become severely ill and hospitalised usually have additional risk factors, such as

advanced age, obesity, diabetes mellitus, hypertension, ischemic heart disease, and perhaps active malignancies, leading to an increased risk of coagulopathy in these patients.<sup>19</sup>

### 3.2 | The coronavirus disease 2019 vaccine-related thrombosis

The risk factors associated with VITT are also probably the same as the Virchow triad. Nonetheless, it is vital to mention that an undetected SARS-CoV-2 infection at the time of vaccination can also be another potential triggering factor.<sup>20</sup> Moreover, VITT may also occur in patients with a pre-existing hypercoagulable state or an autoimmune disorder, such as factor V Leiden, protein C/S deficiency, or antiphospholipid syndrome, demonstrating the importance of taking extra precautions when vaccinating these populations, especially with adenoviral vector vaccines.<sup>21</sup> Other potential risk factors include female sex and younger age,<sup>21</sup> although the impact of age remains controversial.<sup>22</sup> In September 2021, PRAC further updated the product information by removing the current statement that reported thrombosis with thrombocytopenia syndrome cases occurred mostly in women under 60 years of age since the age and sex imbalance seemed smaller than previously observed. Nevertheless, the exact effect of prior coagulopathy in vaccinated people (or their family), hormonal medications, autoimmune disorders, history of thrombocytopenia, or pregnancy as factors triggering VITT is unknown.<sup>23</sup>

## 4 | PATHOPHYSIOLOGY

### 4.1 | SARS-CoV-2-related thrombosis

In Patients exhibiting severe Covid-19 infection, thrombocytopenia is one of the most clinical characteristic features.<sup>24</sup> According to McFadyen et al.<sup>24</sup> thrombocytopenia is associated with a five-fold increased risk of severe Covid-19, although it is not a common finding in non-severe cases. In severe cases, SARS-CoV-2-activated platelets secrete a group of different chemokines, including PF4, CCL3, CCL7, CXCL1, CXCL5, and CXCL7, which will induce the recruitment of white blood cells, granting platelets a pro-inflammatory phenotype in the setting of SARS-CoV-2 infection.<sup>24</sup> Thus, these patients may develop thromboembolic complications via mechanisms, such as platelet activation, coagulopathy, neutrophil extracellular traps, and a cytokine storm (Figure 1).<sup>25</sup> Moreover, a study by Koupenova et al.<sup>26</sup> demonstrated that SARS-CoV-2 RNA could be detected with different levels in all Covid-19 patients' platelets because platelets can rapidly internalise SARS-CoV-2 either through ACE2 or by taking up virions attached to microparticles.<sup>26</sup> Internalisation of SARS-CoV-2 initiates platelet death programs, leading to the release of platelet content and subsequent reduction of their functionality, which can contribute to dysregulated immunity and thrombosis.<sup>26</sup>

### 4.2 | The coronavirus disease 2019 vaccine-related thrombosis

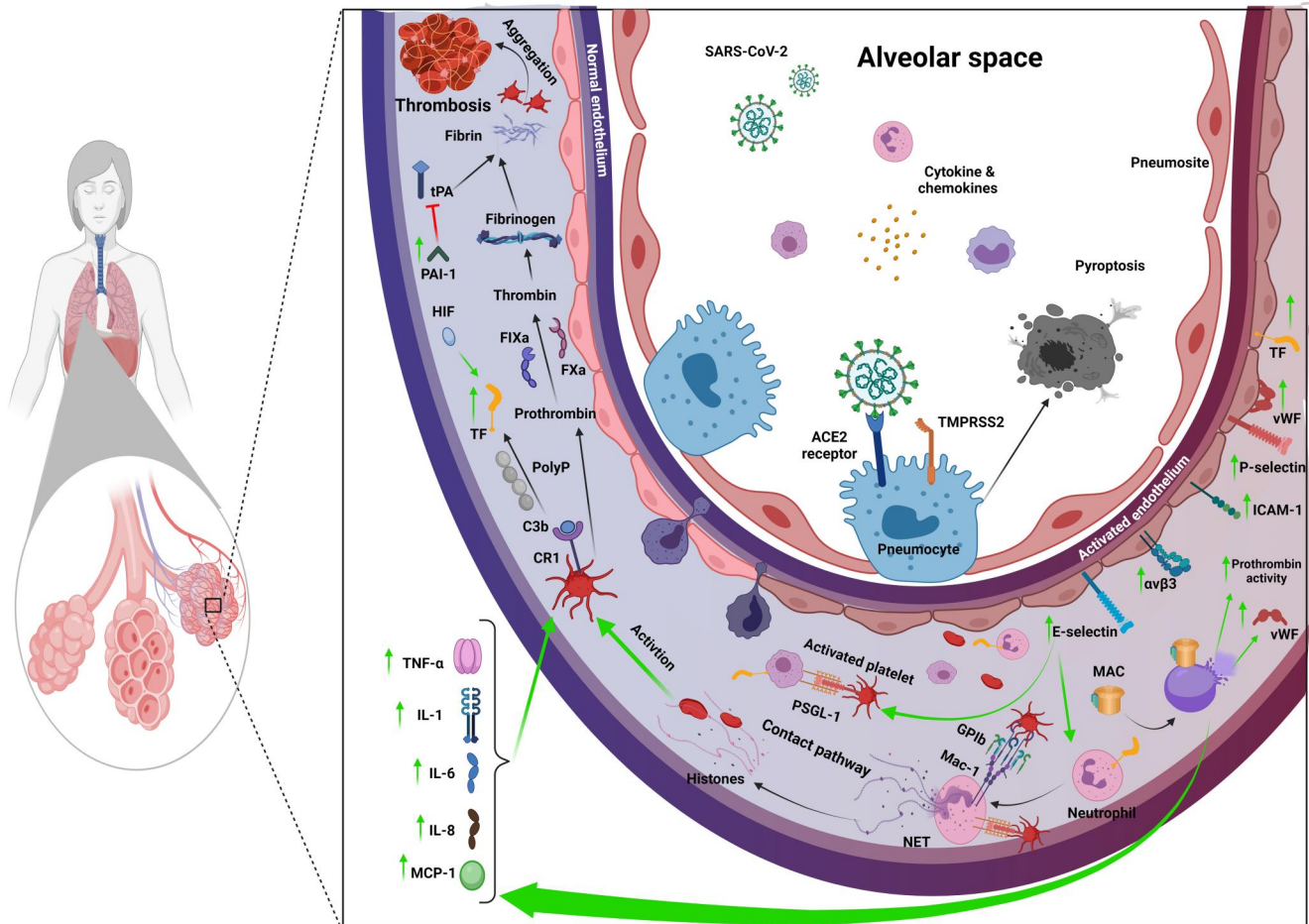
The complete pathophysiology of VITT has been discussed previously.<sup>27</sup> However, in summary, the proposed mechanism of VITT includes anti-PF4 antibody formation, excessive platelet activation, aggregation, and consumption, somewhat similar to heparin-induced thrombocytopenia (HIT), but without exposure to heparin itself.<sup>28</sup> Recently, the antibody epitopes in VITT were determined using alanine-scanning mutagenesis.<sup>29</sup> It was found that the binding of anti-PF4 antibodies from patients with VITT was restricted to eight surface amino acids on PF4, all of which were located within the heparin-binding site, and that the binding was inhibited by heparin.<sup>29</sup> By contrast, antibodies from patients with HIT bound to amino acids corresponding to two different sites on PF4. It was also revealed that VITT anti-PF4 antibodies had a stronger binding response to PF4 and PF4-heparin complexes than HIT anti-PF4 antibodies, albeit with similar dissociation rates.<sup>29</sup> Thus, these findings suggest that VITT antibodies can mimic the effect of heparin by binding to a similar site on PF4, allowing PF4 tetramers to cluster and form immune complexes, which in turn causes platelets activation via low-affinity platelet FcγIIa receptors (FcγRIIa) (Figure 2).<sup>11,29</sup>

## 5 | MANIFESTATIONS

### 5.1 | SARS-CoV-2-related thrombosis

Arterial thrombosis in the settings of Covid-19 has been commonly reported, and its manifestations depend on the specific artery involved. For example, thrombosis of the coronary artery may lead to myocardial infarction<sup>30</sup>; pulmonary arterial thrombosis can have a wide range of manifestations, from acute dyspnoea to asymptomatic and undiagnosed thrombosis, which can only be identified during an autopsy<sup>31</sup>; arterial thrombosis in the central nervous system may lead to cerebrovascular events and stroke<sup>32</sup>; intraluminal carotid artery thrombosis may present itself with symptoms of acute ischemic stroke<sup>33</sup>; central retinal artery thrombosis can manifest itself with symptoms of anterior ischaemic optic neuropathy<sup>34</sup>; acute PE can appear as abrupt dyspnoea and haemoptysis, which can rapidly progress to haemodynamic instability and death<sup>35</sup>; acute aorto-iliac and mesenteric arterial thrombosis may become manifest as acute mesenteric ischemia and acute abdominal pain<sup>36</sup>; and peripheral arterial thrombosis, such as lower extremity arterial thrombosis, can result in acute limb ischemia, claudication, and rarely amputation.<sup>37,38</sup>

Venous thromboembolism (VTE) has been commonly found in the Covid-19 setting, with slightly different manifestations, including CVST, with various presentations, such as new-onset seizures, headaches, hemiplegia, or aphasia<sup>39</sup>; superficial and deep venous thrombosis (SVT/DVT), leading to limb swelling and redness<sup>40,41</sup>; pulmonary venous thrombosis, with haemoptysis, cough or progressive dyspnoea<sup>42</sup>; portal or splanchnic vein thrombosis,

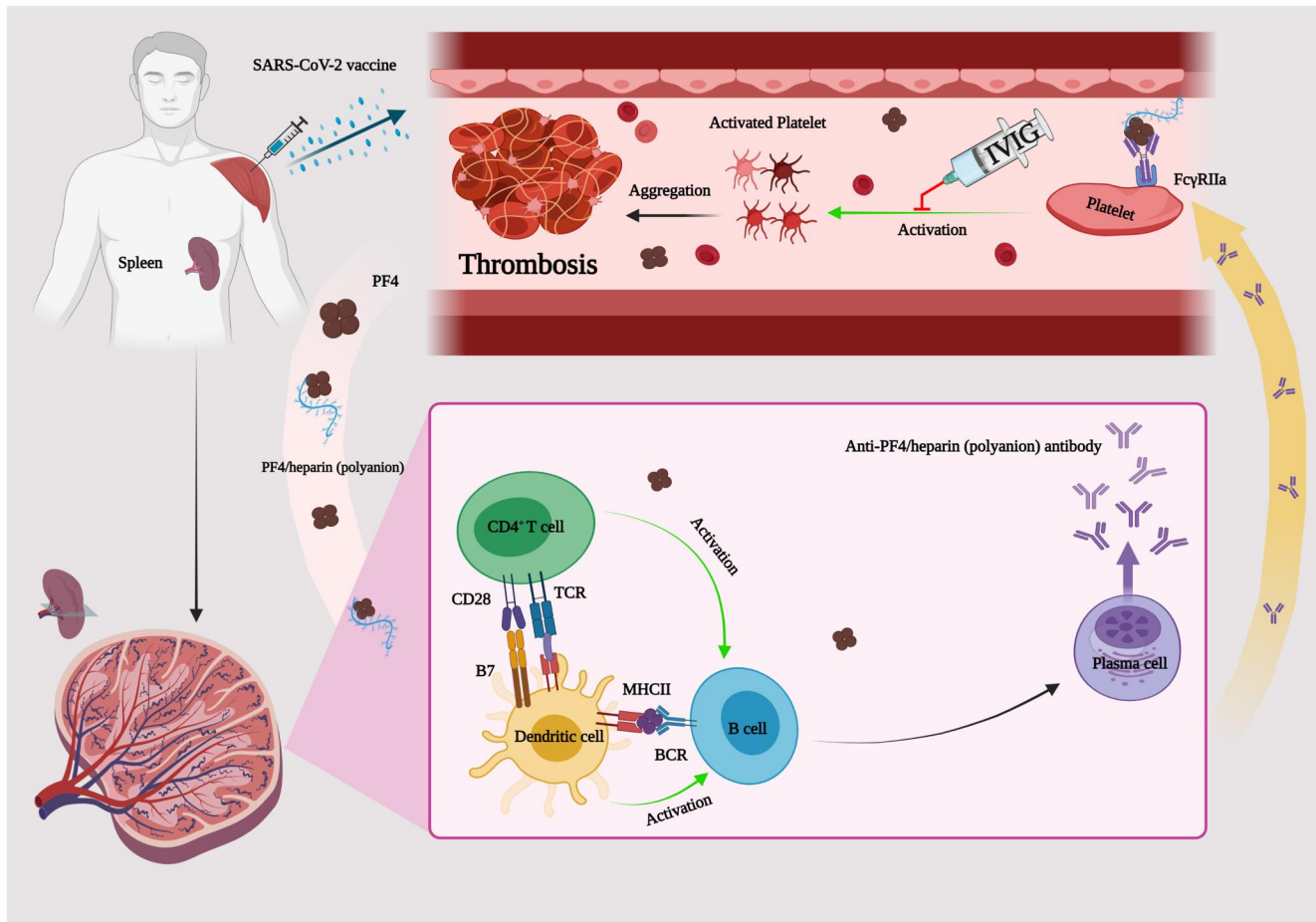


**FIGURE 1** SARS-CoV-2-induced thrombosis. SARS-CoV-2 travels to the lungs and attaches to the angiotensin-converting enzyme 2 (ACE2) receptor on the membrane of the pneumocyte cells of alveoli, triggering immune cells chemotaxis from the arteries and secreting cytokines & chemokines. Eventually, these cytokines cause pyroptosis in the pneumocyte cells, and simultaneously, the production of E-selectin,  $\alpha\text{v}\beta\text{3}$ , ICAM-1, P-selectin, vWF, and TF increases, activated by the adhesion of active platelets to the neutrophil-TF-PSGL-1-P-selectin complex. At the same time, due to this increment, the neutrophil-TF complex will undergo some intracellular changes, commonly known as NETosis, to which the PSGL-1-P-selectin-active platelet complex and the Mac-1-GPIb-activated platelet complex are attached. Platelets are activated when inactive platelets collide with the NET-histones complex. The MAC complex is activated and eliminates the cells, thus, increasing vWF production and prothrombin activity. Cell destruction will increase cytokine secretion, such as TNF- $\alpha$ , IL-1, IL-6, IL-8, and MCP-1. These cytokines form the active platelet-CR1-C3b complex, which enhances TF production with the help of PolyP. This complex can also produce thrombin by affecting prothrombin via factor IXa and factor Xa. Thrombin is converted to fibrinogen, increasing the production of PAI-1 that would block tPA activity. Moreover, fibrinogen is converted to fibrin, which, when added to aggregated platelets, will cause thrombosis. ACE2, angiotensin-converting enzyme two; GPIb, glycoprotein Ib; CR1, complement receptor 1; FIXa, factor IXa; FXa, factor Xa; ICAM-1, intercellular adhesion molecule 1; IL-1, interleukin-1; IL-6, interleukin-6; IL-8, interleukin-8; Mac-1, macrophage-1 antigen; MAC, membrane attack complex; MCP-1, monocyte chemoattractant protein 1; NET, neutrophil extracellular traps; PAI-1, plasminogen activator inhibitor-1; PSGL-1, P-selectin glycoprotein ligand-1; TF, tissue factor; TNF- $\alpha$ , tumour necrosis factor- $\alpha$ ; tPA, tissue plasminogen activator; vWF, Von Willebrand factor

presenting with acute abdominal pain<sup>43-46</sup>; and more rarely, ovarian venous thrombosis, presenting with abdominal pain and vomiting.<sup>47</sup> Non-vessel thrombotic complications may also occur in this setting, such as extracorporeal membrane oxygenation, continuous veno-venous hemofiltration circuit, coronary stent, and bioprosthetic mitral valve thrombosis.<sup>48-53</sup> Moreover, thrombotic microangiopathy has been reported in adults and children with Covid-19, presenting hemolytic anemia, thrombocytopenia, and occasionally end-organ failure.<sup>54</sup>

## 5.2 | The coronavirus disease 2019 vaccine-related thrombosis

Thrombosis induced by anti-SARS-CoV-2 vaccines has similar manifestations as the thromboses in the setting of de novo SARS-CoV-2 infection. However, vaccine-induced thromboses have mainly been seen to involve blood vessels in unusual locations, such as splanchnic (mesenteric, hepatic, or portal) veins (manifesting with acute abdominal pain and vomiting), adrenal veins (presenting with adrenal



**FIGURE 2** Covid-19 vaccine-induced thrombosis. After injection, the vaccine elements enter the bloodstream through vascular endothelial cells, leading to platelet factor 4 (antiplatelet factor 4 (PF4)) production. The produced PF4 and PF4-heparin (polyanion) complex travel to the spleen, where they could activate B cells and CD4<sup>+</sup> T cells through activating dendritic cells in the white spleen pulp. CD4<sup>+</sup> T cells also themselves can increase the activity of B cells. B cells are then converted to plasma cells, secreting anti-PF4-heparin (polyanion) antibodies, which subsequently enter the bloodstream. Then, the formed antibody-antigen complex would bind to the FcγRIIIa on the surface of inactive platelets, resulting in the triggering and activating of them, which subsequently can lead to thrombosis. One important therapeutic option in the vaccine-induced immune thrombotic thrombocytopenia setting is the intravenous immunoglobulin (anticoagulants and intravenous immunoglobulin (IVIg)) administration that would inhibit platelet activation. HIPA assay, heparin-induced platelet aggregation assay; ITP, immune thrombocytopenia; IVIG, intravenous immunoglobulin; PF4, platelet factor 4

failure), and cerebral veins (exhibiting headaches, visual disturbances, seizures, mental status changes, or coma).<sup>55-57</sup> Moreover, pulmonary artery thrombosis and DVT cases have also been reported following vaccination.<sup>58-60</sup> Ultimately, infrequent events, such as ophthalmic vein thrombosis, and acute coronary artery thrombosis, have also been reported in these settings.<sup>61,62</sup> In general, cerebrovascular accidents, myocardial infarction, and pulmonary thromboembolism (PTE) have been the most commonly reported thromboembolic events following the administration of Covid-19 vaccines.<sup>63</sup> It is vital to mention that venous involvement is more commonly seen than arterial thrombosis.<sup>64</sup> Furthermore, the characteristics of thrombotic events after Covid-19 vector-based vaccines differ between the two adenoviral vector vaccines, with DVT/PTE and arterial thrombosis being more frequently reported following the AstraZeneca vaccine than the Johnson & Johnson/Janssen vaccine, probably due to the higher numbers of the AstraZeneca vaccine administered.<sup>65</sup>

## 6 | LABORATORY DATA

### 6.1 | SARS-CoV-2-related thrombosis

The D-dimer levels usually increase in any thrombotic event, regardless of its aetiology.<sup>66</sup> However, this marker is also a nonspecific indicator of inflammation that may increase in several other conditions, including sepsis, surgery, pancreatitis, and even pregnancy, and thus, it has a low level of specificity for thrombosis.<sup>67</sup> Moreover, it has been previously shown that D-dimer elevation in the context of Covid-19 could suggest increased severity and mortality.<sup>68</sup> Therefore, elevated D-dimer levels are observed during severe cases of Covid-19 infection, even in the absence of a thrombotic event.<sup>69</sup> Furthermore, its increment on admission can act as a prognostic criterion for bleeding and thrombosis in these patients. Other predictive markers of thrombosis in a hospitalised SARS-CoV-2-infected

patient include increased C-reactive protein, erythrocyte sedimentation rate, ferritin, procalcitonin, and decreased fibrinogen.<sup>70</sup>

## 6.2 | The coronavirus disease 2019 vaccine-related thrombosis

In any individual with a suspected post-vaccination thromboembolic event, a full haematologic workup should be carried out, including a complete blood count, peripheral blood smear, D-dimer, fibrinogen, coagulation tests (prothrombin time, partial thromboplastin time, and international normalized ratio), renal (blood urea nitrogen, and creatinine) and liver (aspartate aminotransferase, alanine aminotransferase, alkaline phosphatase) function tests, electrolytes (sodium, chloride, potassium, bicarbonate), and anti-PF4/heparin (polyanion) antibody test. Based on the mentioned laboratory assays, the VITT diagnosis can be divided into four categories proposed by Pavord et al.<sup>71</sup>: definite, probable, possible, and unlikely. A definite VITT diagnosis is made when all of these criteria are met: (1) onset of symptoms 5–30 days after vaccination (or  $\leq 42$  days in patients with isolated DVT or PE), (2) presence of thrombosis, (3) thrombocytopenia (platelet count  $< 150,000/\mu\text{l}$ ), (4) D-dimer level  $> 4000$  fibrinogen-equivalent units (FEU), and (5) positive anti-PF4 antibodies on enzyme-linked immunosorbent assay (ELISA). A probable VITT diagnosis is indicated when D-dimer level  $> 4000$  FEU, but one criterion is not met (timing, thrombosis, thrombocytopenia, or anti-PF4 antibodies), or D-dimer level is unknown or between 2000 and 4000 FEU and all other criteria are met. A possible VITT diagnosis is when D-dimer level is unknown or 2000–4000 FEU with one other criterion not met or two other criteria not met (timing, thrombosis, thrombocytopenia, or anti-PF4 antibodies). Finally, VITT is deemed unlikely in a patient if platelet count  $< 150,000/\mu\text{l}$ , D-dimer level  $< 2000$  FEU, and there is no evidence of thrombosis, or if thrombosis is evident, but the platelet count  $> 150,000/\mu\text{l}$  and D-dimer level  $< 2000$  FEU, regardless of anti-PF4 antibody result, and alternative diagnosis is more likely. In all settings, consultation with a hematologist is highly recommended.

Another criterion for VITT diagnosis is the VITT-adapted 4 Ts scoring system.<sup>72</sup> In this system, each parameter, that is, thrombocytopenia, timing, thrombosis, and other cause of thrombosis or thrombocytopenia, will be given a score from 0 to 2. Then, based on the patient's total score, the VITT diagnosis could be interpreted as low probability if the score is 0–3, intermediate probability if the score is 4–5, or high probability if the score is 6–8.<sup>72</sup>

## 7 | DIAGNOSIS

### 7.1 | SARS-CoV-2-related thrombosis

If clinically suspected, VTE should be confirmed with sensitive imaging modalities, such as magnetic resonance venography (MRV),

magnetic resonance angiography, computed tomography pulmonary angiogram (CTPA), pulmonary ventilation/perfusion (V/Q) scan, or colour Doppler ultrasonography.<sup>73</sup> However, it is vital to mention that elevated D-dimers without clinical manifestation of VTE do not warrant diagnostic imaging.<sup>74</sup>

### 7.2 | The coronavirus disease 2019 vaccine-related thrombosis

The necessary laboratory procedure for VITT diagnosis is detecting anti-PF4/heparin (polyanion) antibodies via ELISA.<sup>75</sup> All other methods for detecting these antibodies, such as rapid immunoassay and chemiluminescence immunoassay, have low sensitivity and thus may produce false negatives.<sup>76</sup> Therefore, a negative ELISA rules out VITT and indicates other possible aetiologies. Nonetheless, a positive test mandates further confirmatory assays, including the SRA, heparin-induced platelet activation assay, platelet aggregation test, heparin-induced multiple electrode aggregometry, PF4-dependent P-selectin expression assay, PF4-SRA, or PF4/heparin-SRA.<sup>77</sup> Like any other thromboembolic event, definitive diagnostic imaging should also be performed based on the clinical presentations in a suspected case of VITT. For example, patients presenting with sudden onset dyspnoea and suspicion of PTE should undergo a CTPA or V/Q scan, while for those with new-onset limb swelling and pain, performing a colour Doppler ultrasonography is highly recommended. Moreover, in cases with suspected post-vaccination CVST, performing a CT venography or MRV seems reasonable, whereas, in patients with abdominal symptoms, an intravenous contrast-enhanced CT scan would be the most appropriate diagnostic tool.

## 8 | TREATMENT

### 8.1 | SARS-CoV-2-related thrombosis

Patients with confirmed VTE should be treated according to the established guidelines of thromboembolism therapy. However, low-molecular-weight heparin (LMWH) and direct oral anticoagulants (DOACs) are the preferred therapeutic agents in inpatient and post-discharge settings, respectively.<sup>78</sup> Although it was believed that if the patient's respiratory condition deteriorates or develops into ARDS, a transition from a prophylactic or intermediate-dose to a therapeutic dose regimen seems reasonable, even in the absence of confirmed VTE,<sup>79–81</sup> a recent clinical trial refutes this hypothesis.<sup>82</sup> A proposed mechanism for this observation could be that in the presence of marked pulmonary inflammation in critically ill Covid-19 patients, administration of therapeutic-dose anticoagulants may exacerbate the alveolar haemorrhage, leading to worse clinical outcomes.<sup>82</sup> It is also of note that the total duration of anticoagulant therapy should be at least 3 months following a confirmed thrombotic event.<sup>83</sup>

## 8.2 | The coronavirus disease 2019 vaccine-related thrombosis

The primary medications for VITT management include IVIG and anticoagulants. IVIG's recommended dose and duration is 1–2 g/kg/day for 2 days. For anticoagulation therapy, parenteral direct thrombin inhibitors, such as argatroban or bivalirudin, are recommended for first-line therapy, and DOACs, such as apixaban or rivaroxaban, or synthetic inhibitors of factor Xa, such as fondaparinux or danaparoid, could be used as alternatives. Antiplatelet agents, including aspirin and platelet transfusions, should be avoided<sup>84</sup> (Figure 3). Heparin is also contraindicated in the context of VITT, except when the anti-PF4/heparin (polyanion) antibody ELISA is negative, disseminated intravascular coagulation is ruled out, and the platelet count is normal ( $>150,000/\mu\text{l}$ ). Warfarin and other vitamin K antagonists are also contraindicated if thrombocytopenia is present. Corticosteroids are recommended only in the case of severe thrombocytopenia, or if there is a shortage/inaccessibility to IVIG, with a 40 mg dose of dexamethasone daily (or equivalent doses of other corticosteroids) for 4 days.<sup>85</sup> Fibrinogen correction with fibrinogen concentrate or cryoprecipitate can be considered if excessive and uncontrollable bleeding occurs or very low fibrinogen values are present.<sup>86</sup> Inhibitors of Bruton tyrosine kinase (Btk) have also been proposed as a treatment modality for VITT.<sup>87</sup> In the case of a significant CVST, thrombectomy or surgical intervention can be considered.<sup>88</sup> Moreover, due to the probability of thrombocytopenia recurrence after completing the IVIG course, monitoring the platelet count during hospitalisation and after discharge is highly recommended.<sup>72</sup> The total duration of treatment in a VITT patient is 3 months after normalisation of the platelet count, as long as no further thrombosis occurs, similar to de novo infection-induced thrombosis.<sup>72</sup>

## 9 | PREVENTION

### 9.1 | SARS-CoV-2-related thrombosis

Due to the increased risk of thrombosis in severe forms of Covid-19, LMWH at intermediate doses or unfractionated heparin infusions is recommended for patients with high D-dimers or those admitted to an intensive care unit (ICU), even in the absence of thromboembolic consequences.<sup>89,90</sup> Moreover, if not contraindicated, a prophylactic dose of LMWH should be considered in all patients requiring hospitalisation, even non-critically ill cases.<sup>91</sup> Nevertheless, it should be pointed out that recent data indicate that there is no superiority of intermediate-dose versus the standard low-dose thromboprophylaxis, demonstrating the fact that empirical use of intermediate-dose prophylactic anticoagulation in unselected patients admitted to the ICU with Covid-19 may not be beneficial.<sup>92</sup> On the other hand, some dose increment in particular clinical settings, such as a 50% increase in the thromboprophylaxis dose in

obese patients, is mandated.<sup>93</sup> Hospitalised patients who meet high VTE risk criteria should be recommended to take the thromboprophylaxis dose until 14–30 days post-discharge.<sup>94</sup> In this condition, the administration of a DOAC seems more convenient for patients.<sup>95</sup> However, the exact dose and duration of the anticoagulant thromboprophylaxis, including post-hospital discharge prophylaxis, is still controversial in SARS-CoV-2-infected patients.<sup>96</sup> In patients with contraindications of pharmacological thromboprophylaxis (e.g., thrombocytopenia or impaired coagulation tests), mechanical methods should be considered, including the use of intermittent pneumatic compression devices.<sup>97</sup>

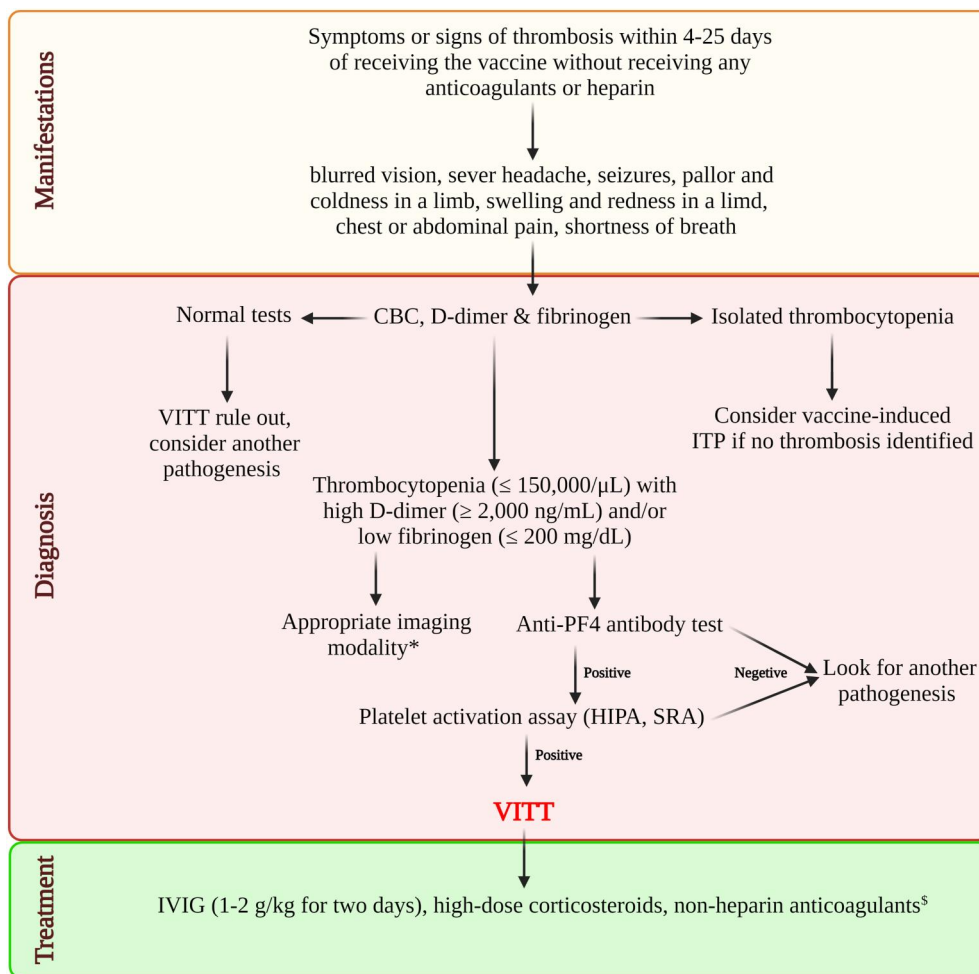
### 9.2 | The coronavirus disease 2019 vaccine-related thrombosis

Considering numerous VITT reports in younger individuals, authorities in many countries prohibit the administration of vector-based vaccines in these populations. Furthermore, a negative SARS-CoV-2 reverse-transcriptase-polymerase-chain-reaction (RT-PCR) test at the time of vaccination may lower the rate of VITT and other Covid-19-related complications. It is worth mentioning that aspirin plays no role in preventing VITT and may exacerbate the risk of bleeding or even blunt the vaccination-induced immune response.

## 10 | VACCINE-INDUCED THROMBOCYTOPENIA

Recently, Salih et al. developed a new term, vaccine-induced thrombocytopenia (VIT) or pre-VITT syndrome, described as VIT without associated CVST or other thromboses mainly manifested as severe headaches. In this report, 11 patients were presented with severe headaches without any thromboses 5–18 days after receiving the AstraZeneca Covid-19 vaccine.<sup>98</sup> These patients had thrombocytopenia, high D-dimers, and anti-PF4-heparin IgG antibodies. During the follow-up period, 3 patients developed intracranial haemorrhage, of which 2 patients were later diagnosed with a newly-onset CVST.<sup>98</sup> Thrombotic complications were not apparent in seven of these patients, and all except one of these 7 patients were treated according to the standard VITT treatment plan (IVIG, glucocorticoids, therapeutic-dose anticoagulants) within 5 days of their headache onset. On the other hand, for the other 4 patients who developed thrombosis, therapeutic-dose anticoagulants were either not initiated until 6–9 days after headache onset or were halted prior to CVST development.<sup>98</sup>

Despite being already reported as one of the typical signs and symptoms of CVST-associated VITT, this study argued that thrombocytopenia with severe headache, high D-dimers, and anti-PF4-heparin IgG antibodies could be instead, a sign of VIT that may further progress to VITT.<sup>21,86,98</sup> Thus, clinicians should be aware that severe headache in a typical setting of VITT (recent history of vaccination with adenoviral vector Covid-19 vaccines, high D-dimers,



**FIGURE 3** A proposed diagnostic and therapeutic algorithm for vaccine-induced immune thrombotic thrombocytopenia (VITT). If a patient with a history of The coronavirus disease 2019 (Covid-19) vaccination, especially with adenoviral vector vaccines, in the past 5–20 days and was presented with symptoms, such as blurred vision, severe headache, seizures, pallor, cold, swelling, and redness in the limbs, chest or abdominal pain, and shortness of breath, VITT can be suspected, necessitating further investigations. Thus, CBC, D-dimer, and fibrinogen tests should be performed. A VITT diagnosis would be highly unlikely and ruled out if the test results are normal. On the other hand, if only thrombocytopenia (platelet count  $\leq 150,000/\mu\text{L}$ ) is detected in the CBC, a diagnosis of vaccine-induced ITP flare-up or, especially if a severe headache is present, VIT could be considered for the patient. However, if thrombocytopenia, high D-dimers ( $\geq 2000 \text{ ng/ml}$ ), and low fibrinogen ( $\leq 200 \text{ mg/dl}$ ) are present, further imaging and serologic tests are mandated, of which anti-PF4-heparin IgG antibody testing via antibodies on enzyme-linked immunosorbent assay or immunoassay is the most vital. A platelet activation assay, such as HIPA assay, or serotonin release assay (SRA), should be performed if positive. If also positive, VITT diagnosis will be confirmed. After confirmation, anticoagulants and IVIG (1–2 g/kg for 2 days), high-dose corticosteroids, and non-heparin anticoagulants should be immediately initiated for the patient. \* Magnetic resonance venography (MRV), magnetic resonance angiography (MRA), computed tomography pulmonary angiogram (CTPA), pulmonary ventilation/perfusion (V/Q) scan, or colour Doppler ultrasonography. <sup>§</sup> Rivoraxaban, apixaban, argatroban, dabigatran, bivalirudin, fundaparinux, danaparoid. CBC, Complete blood count; HIPA assay, Heparin-induced platelet aggregation assay; ITP, Immune thrombocytopenia; IVIG, Intravenous immunoglobulin; PF4, Platelet factor 4; SRA, Serotonin release assay; VITT, Vaccine-induced immune thrombotic thrombocytopenia; VIT, Vaccine-induced thrombocytopenia

and anti-PF4-heparin IgG antibodies) may be a sign of micro-thrombosis in smaller cortical vessels, implicating a possible chance of subsequent CVST development.<sup>98</sup> Therefore, patients with severe headaches 5–20 days after vaccination with adenoviral vector Covid-19 should immediately undergo further VITT diagnostic tests. If proven high-risk for developing CVST, immediate administration of IVIG, among others, could prevent this catastrophic adverse event from happening.<sup>98</sup>

## 11 | PUBLIC HEALTH CONSEQUENCES

### 11.1 | Interruption of vaccine campaigns

For decades, public concerns about vaccines for disease prevention have circulated, fuelled by extensive media coverage capitalising on exaggerated headlines.<sup>99,100</sup> This can substantially impact campaigns intended to increase vaccination uptake and subsequently



increase herd immunity, with even the slightest uncertainty about safety causing immediate halts in public confidence.<sup>99,101</sup> Moreover, these effects can be extremely long-lasting, such as the unfounded link between vaccination and autism.<sup>100</sup> An article published in 1998 suggested a link between the measles, mumps, and rubella vaccine and autism,<sup>102</sup> which was later found fraudulent.<sup>103</sup> Despite subsequent rigorous evidence reporting no evidence of any association between the two,<sup>104</sup> public memory of these headlines has retained the link regardless, evident in a 2017 survey of 1000 Canadian parents where 28% still believed or were uncertain about whether a link between vaccines and autism existed.<sup>105</sup> Social media is another relatively new source of information and misinformation fuelling vaccine hesitancy among some subscribers, potentially a more significant concern than mainstream media due to the lack of editorial oversight.<sup>106</sup> Concerns around vaccine safety due to issues, such as thromboembolic events, have resulted in suspension to national vaccine rollout in some countries, contributing to substantial drops in public confidence.<sup>107</sup> However, some studies are reporting sustained willingness by the public to vaccinate against Covid-19, with other manufacturers apart from AstraZeneca.<sup>108,109</sup>

## 11.2 | Countering negative vaccine connotations

Understanding how the media influences public health campaigns has never been more critical. The ability to immediately share information and communicate has created a new age where both positive and negative messages can be shared for people to consider, regardless of whether the content is true or false. Policymakers and government officials need to rapidly increase their digital communication skills as traditional educational campaigns urging people into certain behaviours based on scare tactics or simply sharing health advice is not creating the impact it once did.<sup>110,111</sup> Indeed, public health campaigns need to embrace innovative technology and work with mainstream and social media influencers to provide reliable, timely, and accurate advice.<sup>106</sup>

## 12 | CONCLUSION

In summary, both SARS-CoV-2 infection and Covid-19 vaccines may trigger thromboembolic events, with the first one posing more significant risks of thrombotic events. Thus, these events must be taken seriously, and the appropriate laboratory assays and imaging modalities should be utilised to confirm the diagnosis. If confirmed, IVIG, high-dose corticosteroids, and anticoagulants should be administered to decrease VITT's risk of morbidity and mortality. Nevertheless, it is vital to mention that although such catastrophic adverse events may happen following the Covid-19 vaccination, they should not prevent people from being vaccinated.

## ACKNOWLEDGEMENTS

The authors would like to thank the Clinical Research Development Center, Imam Reza Hospital, Kermanshah University of Medical Sciences, and the Department of infectious diseases, School of Medicine, Babol University of Medical Sciences.

## CONFLICT OF INTEREST

Thrombosis with thrombocytopenia syndrome reports that he provides strategic and scientific recommendations as a member of the Advisory Board and speaker for Novocure, Inc. and also as a member of the Advisory Board to Galera Therapeutics, which are not in any way associated with the content or disease site as presented in this manuscript. All other authors have no relevant financial interests to be declared.

## AUTHOR CONTRIBUTION

Zeinab Mohseni Afshar: Data collection and writing the manuscript. Arefeh Babazadeh: Data collection and helped with manuscript writing. Mohammad Barary: Data collection, helped with manuscript writing, and contributed substantial revisions to the manuscript's content. Rezvan Hosseinzadeh: Visualization, software, and helped with manuscript writing. Amirmasoud Alijanpour: Helped with manuscript writing and contributed substantial revisions to the manuscript's content. Seyed Rouhollah Miri: Data collection and helped with manuscript writing. Terence T. Sio: Contributed substantial revisions to the manuscript's content. Mark J. M. Sullman: Contributed substantial revisions to the manuscript's content. Kristin Carson-Chahhoud: Contributed substantial revisions to the manuscript's content. Florian Langer: Contributed substantial revisions to the manuscript's content. Soheil Ebrahimpour: Design of the research study, supervision.

## DATA AVAILABILITY STATEMENT

Data sharing is not applicable to this article as no new data were created or analyzed in this study.

## ORCID

Mohammad Barary  <https://orcid.org/0000-0001-8733-9370>

## REFERENCES

1. Javanian M, Bayani M, Shokri M, et al. Risk factors for mortality of 557 adult patients with COVID 19 in Babol, Northern Iran: a retrospective cohort study. *Bratisl Lek Listy*. 2021;122(1):34-38.
2. Javanian M, Bayani M, Shokri M, et al. Clinical and laboratory findings from patients with COVID-19 pneumonia in Babol North of Iran: a retrospective cohort study. *Rom J Intern Med*. 2020;58(3):161-167.
3. Piazza G, Morrow DA. Diagnosis, management, and pathophysiology of arterial and venous thrombosis in COVID-19. *JAMA*. 2020;324(24):2548-2549.
4. Burn E, Gol S-IJ, register number EUPAS40414 E. *NATURAL HISTORY OF COAGULOPATHY AND USE OF ANTI-THROMBOTIC AGENTS IN COVID-19 PATIENTS AND PERSONS VACCINATED*

- AGAINST SARS-COV-2-REPORT 1: BACKGROUND RATES OF EVENTS OF INTEREST; 2021.
5. Middeldorp S, Coppens M, van Haaps TF, et al. Incidence of venous thromboembolism in hospitalized patients with COVID-19. *J Thromb Haemost.* 2020;18(8):1995-2002.
  6. Kunutsor SK, Laukkanen JA. Incidence of venous and arterial thromboembolic complications in COVID-19: a systematic review and meta-analysis. *Thromb Res.* 2020;196:27-30.
  7. Committee PRA. COVID-19 Vaccine Safety Update. European Medicines Agency; 2021.
  8. Schultz NH, Sorvoll IH, Michelsen AE, et al. Thrombosis and thrombocytopenia after ChAdOx1 nCoV-19 vaccination. *N Engl J Med.* 2021;384(22):2124-2130.
  9. Pishko AM, Cuker A. Thrombosis after vaccination with messenger RNA-1273: is this vaccine-induced thrombosis and thrombocytopenia or thrombosis with thrombocytopenia syndrome? *Ann Intern Med.* 2021;174(10):1468-1469.
  10. Sangli S, Virani A, Cheronis N, et al. Thrombosis with thrombocytopenia after the messenger RNA-1273 vaccine. *Ann Intern Med.* 2021;174(10):1480-1482.
  11. Warkentin TE, Cuker A. COVID-19: vaccine-induced immune thrombotic thrombocytopenia (VITT). *Update May.* 2021;7.
  12. Oliver SE, Gargano JW, Scobie H, et al. The advisory committee on immunization practices' interim recommendation for use of Janssen COVID-19 vaccine—United States, February 2021. *MMWR (Morb Mortal Wkly Rep).* 2021;70(9):329-332.
  13. Bussel J, Connors J, Cines D. *Thrombosis with Thrombocytopenia Syndrome (Also Termed Vaccine-Induced Thrombotic Thrombocytopenia. Version 1.2).* American Society of Hematology; 2021.
  14. Scully M, Singh D, Lown R, et al. Pathologic antibodies to platelet factor 4 after ChAdOx1 nCoV-19 vaccination. *N Engl J Med.* 2021;384(23):2202-2211.
  15. Zhou F, Yu T, Du R, et al. Clinical course and risk factors for mortality of adult inpatients with COVID-19 in Wuhan, China: a retrospective cohort study. *Lancet.* 2020;395(10229):1054-1062.
  16. Hamming I, Timens W, Bulthuis ML, Lely AT, Navis G, van Goor H. Tissue distribution of ACE2 protein, the functional receptor for SARS coronavirus. A first step in understanding SARS pathogenesis. *J Pathol.* 2004;203(2):631-637.
  17. Kollias A, Kyriakoulis KG, Dimakakos E, Poulakou G, Stergiou GS, Syrigos K. Thromboembolic risk and anticoagulant therapy in COVID-19 patients: emerging evidence and call for action. *Br J Haematol.* 2020;189(5):846-847.
  18. Driggin E, Madhavan MV, Bikdeli B, et al. Cardiovascular considerations for patients, health care workers, and health systems during the COVID-19 pandemic. *J Am Coll Cardiol.* 2020;75(18):2352-2371.
  19. Anderson FA, Jr, Spencer FA. Risk factors for venous thromboembolism. *Circulation.* 2003;107(23\_suppl\_1):I-9.
  20. Lippi G, Sanchis-Gomar F, Favaloro EJ, Lavie CJ, Henry BM. Coronavirus disease 2019 (COVID-19)-associated coagulopathy Paper Presented at: *Mayo Clinic Proceedings.* 2020.
  21. Greinacher A, Thiele T, Warkentin TE, Weisser K, Kyrle PA, Eichinger S. Thrombotic thrombocytopenia after ChAdOx1 nCoV-19 vaccination. *N Engl J Med.* 2021;384(22):2092-2101.
  22. Arepally GM, Ortel TL. *Vaccine-Induced Immune Thrombotic Thrombocytopenia (VITT): What We Know and Don't Know.* Blood; 2021.
  23. Pai M, Chan B, Stall N. Vaccine-induced immune thrombotic thrombocytopenia (VITT) following adenovirus vector COVID-19 vaccination. *Science Briefs of the Ontario COVID-19 Science Advisory Table.* 2021;2(17).
  24. McFadyen JD, Stevens H, Peter K. The emerging threat of (Micro)thrombosis in COVID-19 and its therapeutic implications. *Circ Res.* 2020;127(4):571-587.
  25. Moschonas IC, Tselepis AD. SARS-CoV-2 infection and thrombotic complications: a narrative review. *J Thromb Thrombolysis.* 2021;52(1):111-123.
  26. Koupenova M, Corkrey HA, Vitseva O, et al. SARS-CoV-2 initiates programmed cell death in platelets. *Circ Res.* 2021;129(6):631-646.
  27. Mohseni Afshar Z, Babazadeh A, Janbakhsh A, et al. Vaccine-induced immune thrombotic thrombocytopenia after vaccination against Covid-19: a clinical dilemma for clinicians and patients. *Rev Med Virol.* 2021:e2273.
  28. Cines DB, Bussel JB. SARS-CoV-2 vaccine-induced immune thrombotic thrombocytopenia *Mass Medical Soc;* 2021.
  29. Huynh A, Kelton JG, Arnold DM, Daka M, Nazy I. Antibody epitopes in vaccine-induced immune thrombotic thrombocytopenia. *Nature.* 2021;596(7873):565-569.
  30. Solomon MD, McNulty EJ, Rana JS, et al. The Covid-19 pandemic and the incidence of acute myocardial infarction. *N Engl J Med.* 2020;383(7):691-693.
  31. Lax SF, Skok K, Zechner P, et al. Pulmonary arterial thrombosis in COVID-19 with fatal outcome: results from a prospective, single-center, clinicopathologic case series. *Ann Intern Med.* 2020;173(5):350-361.
  32. Beyrouti R, Adams ME, Benjamin L, et al. Characteristics of ischaemic stroke associated with COVID-19. *J Neurol Neurosurg Psychiatry.* 2020;91(8):889-891.
  33. Mohamad AY, Griffith B, Rehman M, et al. Intraluminal carotid artery thrombus in COVID-19: another danger of cytokine storm? *Am J Neuroradiol.* 2020;41(9):1677-1682.
  34. Finsterer J, Scorza FA, Scorza CA, Fiorini AC. Vascular damage may mimic retinitis and optic neuritis in COVID-19. *Curr Eye Res.* 2021;46(12):1934-1935.
  35. Manjunath M, Miranda J, Fraenkel L, et al. *Acute Pulmonary Embolism in Critically Ill Patients with COVID-19.* medRxiv; 2020.
  36. Azouz E, Yang S, Monnier-Cholley L, Arrive L. Systemic arterial thrombosis and acute mesenteric ischemia in a patient with COVID-19. *Intensive Care Med.* 2020;46(7):1464-1465.
  37. Mestres G, Puigmacia R, Blanco C, Yugueros X, Esturrica M, Rimbau V. Risk of peripheral arterial thrombosis in COVID-19. *J Vasc Surg.* 2020;72(2):756-757.
  38. Goldman IA, Ye K, Scheinfeld MH. Lower-extremity arterial thrombosis associated with COVID-19 is characterized by greater thrombus burden and increased rate of amputation and death. *Radiology.* 2020;297(2):E263-E269.
  39. Cavalcanti DD, Raz E, Shapiro M, et al. Cerebral venous thrombosis associated with COVID-19. *AJNR Am J Neuroradiol.* 2020;41(8):1370-1376.
  40. Voicu S, Bonnin P, Stepanian A, et al. High prevalence of deep vein thrombosis in mechanically ventilated COVID-19 patients. *J Am Coll Cardiol.* 2020;76(4):480-482.
  41. Hesam-Shariati N, Fatehi P, Fathi F, Abouzaripour M, Hesam Shariati MB. A case report of greater saphenous vein thrombosis in a patient with coronavirus (COVID-19) infection. *Trop Dis Travel Med Vaccines.* 2021;7(1):6.
  42. Pasha AK, Rabinstein A, McBane RD. Pulmonary venous thrombosis in a patient with COVID-19 infection. *J Thromb Thrombolysis.* 2021;51(4):985-988.
  43. Franco-Moreno A, Piniella-Ruiz E, Montoya-Adarraga J, et al. Portal vein thrombosis in a patient with COVID-19. *Thromb Res.* 2020;194:150-152.
  44. Del Hoyo J, Lopez-Munoz P, Fernandez-de la Varga M, et al. Hepatobiliary and pancreatic: a fatal case of extensive splanchnic vein thrombosis in a patient with Covid-19. *J Gastroenterol Hepatol.* 2020;35(11):1853.
  45. Carmo Filho A, Cunha BDS. Inferior mesenteric vein thrombosis and COVID-19. *Rev Soc Bras Med Trop.* 2020;53:e20200412.

46. Low SW, Swanson KL, McCain JD, Sen A, Kawashima A, Pasha SF. Gastric ischemia and portal vein thrombosis in a COVID-19-infected patient. *Endoscopy*. 2020;52(12):E465-E466.
47. Mohammadi S, Abouzaripour M, Hesam Shariati N, Hesam Shariati MB. Ovarian vein thrombosis after coronavirus disease (COVID-19) infection in a pregnant woman: case report. *J Thromb Thrombolysis*. 2020;50(3):604-607.
48. Durak K, Kersten A, Grottko O, et al. Thromboembolic and bleeding events in COVID-19 patients receiving extracorporeal membrane oxygenation. *Thorac Cardiovasc Surg*. 2021;69(6):526-536.
49. Hauguel-Moreau M, Lannou S, Bergez L, Mansencal N. Case report of a very late dual coronary stent thrombosis in a patient with coronavirus disease 2019. *European Heart Journal-Case Reports*. 2021;5(6):ytab114.
50. Antuna P, Rivero F, Del Val D, Cuesta J, Alfonso F. Late coronary stent thrombosis in a patient with coronavirus disease 2019. *JAMA Cardiol*. 2020;5(10):1195-1198.
51. Vinnakota S, Jentzer JC, Luis SA. Thrombolysis for COVID-19-associated bioprosthetic mitral valve thrombosis with shock. *Eur Heart J*. 2021;42(39):4093.
52. Hinterseer M, Zens M, Wimmer RJ, et al. Acute myocardial infarction due to coronary stent thrombosis in a symptomatic COVID-19 patient. *Clin Res Cardiol*. 2021;110:302-306.
53. Jenner WJ, Gorog DA. Incidence of thrombotic complications in COVID-19: on behalf of ICODE: the international COVID-19 thrombosis biomarkers colloquium. *J Thromb Thrombolysis*. 2021;52(4):999-1006.
54. Diorio C, McNerney KO, Lambert M, et al. Evidence of thrombotic microangiopathy in children with SARS-CoV-2 across the spectrum of clinical presentations. *Blood Adv*. 2020;4(23):6051-6063.
55. Oldenburg J, Klamroth R, Langer F, et al. Diagnosis and management of vaccine-related thrombosis following AstraZeneca COVID-19 vaccination: guidance statement from the GTH. *Hämostaseologie*. 2021;41(03):184-189.
56. Mehta PR, Apap Mangion S, Bengier M, et al. Cerebral venous sinus thrombosis and thrombocytopenia after COVID-19 vaccination - a report of two UK cases. *Brain Behav Immun*. 2021;95:514-517.
57. Umbrello M, Brena N, Vercelli R, et al. Successful treatment of acute spleno-porto-mesenteric vein thrombosis after ChAdOx1 nCoV-19 vaccine. A case report. *J Crit Care*. 2021;65:72-75.
58. Carli G, Nichele I, Ruggeri M, Barra S, Tosoletto A. Deep vein thrombosis (DVT) occurring shortly after the second dose of mRNA SARS-CoV-2 vaccine. *Intern Emerg Med*. 2021;16(3):803-804.
59. Haakonsen HB, Nystedt A. Deep vein thrombosis more than two weeks after vaccination against COVID-19. *Tidsskrift Den norske legeförening*. 2021;141.
60. Jones M, Boisvert A, Landry J, Petrasko PF. Limb ischemia and pulmonary artery thrombosis after the ChAdOx1 nCoV-19 (Oxford-AstraZeneca) vaccine: a case of vaccine-induced immune thrombotic thrombocytopenia. *CMAJ (Can Med Assoc J)*. 2021;193(24):E906-E910.
61. Tajstra M, Jaroszewicz J, Gasior M. Acute coronary tree thrombosis after vaccination for COVID-19. *JACC Cardiovasc Interv*. 2021;14(9):e103-e104.
62. McDonnell T, Cooksley T, Jain S, McGlynn S. Left inferior ophthalmic vein thrombosis due to VITT (vaccine induced thrombotic thrombocytopenia): a case report. *QJM An Int J Med*. 2021;114(11):810-811.
63. Dal-Re R, Launay O. Public trust on regulatory decisions: the European Medicines Agency and the AstraZeneca COVID-19 vaccine label. *Vaccine*. 2021;39(30):4029-4031.
64. Smadja DM, Yue Q-Y, Chocron R, Sanchez O, Lillo-Le Louet A. Vaccination against COVID-19: insight from arterial and venous thrombosis occurrence using data from VigiBase. *Eur Respir J*. 2021;58(1):2100956.
65. Karron RA, Key NS, Sharfstein JM. Assessing a rare and serious adverse event following administration of the Ad26.COV2.S vaccine. *JAMA*. 2021;325(24):2445-2447.
66. Criel M, Falter M, Jaeken J, et al. Venous thromboembolism in SARS-CoV-2 patients: only a problem in ventilated ICU patients, or is there more to it? *Eur Respir J*. 2020;56(1).
67. Rodelo JR, De la Rosa G, Valencia ML, et al. D-dimer is a significant prognostic factor in patients with suspected infection and sepsis. *Am J Emerg Med*. 2012;30(9):1991-1999.
68. Lippi G, Favaloro EJ. D-dimer is associated with severity of coronavirus disease 2019: a pooled analysis. *Thrombosis haemostasis*. 2020;120(5):876.
69. Zhang L, Yan X, Fan Q, et al. D-dimer levels on admission to predict in-hospital mortality in patients with Covid-19. *J Thromb Haemost*. 2020;18(6):1324-1329.
70. Al-Samkari H, Karp Leaf RS, Dzik WH, et al. COVID-19 and coagulation: bleeding and thrombotic manifestations of SARS-CoV-2 infection. *Blood*. 2020;136(4):489-500.
71. Pavord S, Scully M, Hunt BJ, et al. Clinical features of vaccine-induced immune thrombocytopenia and thrombosis. *N Engl J Med*. 2021;385(18):1680-1689.
72. Warkentin TE, Cuker A. COVID-19: vaccine-induced immune thrombotic thrombocytopenia (VITT). In: Post TW, ed. *UpToDate*. UpToDate; 2021.
73. Bounameaux H, Perrier A, Righini M. Diagnosis of venous thromboembolism: an update. *Vasc Med*. 2010;15(5):399-406.
74. Cui S, Chen S, Li X, Liu S, Wang F. Prevalence of venous thromboembolism in patients with severe novel coronavirus pneumonia. *J Thromb Haemost*. 2020;18(6):1421-1424.
75. Greinacher A, Gopinadhan M, Gunther JU, et al. Close approximation of two platelet factor 4 tetramers by charge neutralization forms the antigens recognized by HIT antibodies. *Arterioscler Thromb Vasc Biol*. 2006;26(10):2386-2393.
76. Nazy I, Sachs UJ, Arnold DM, McKenzie SE, Choi P, Althaus K. Recommendations for the clinical and laboratory diagnosis of vaccine-induced immune thrombotic thrombocytopenia (VITT) for SARS-CoV-2 infections: communication from the ISTH SSC subcommittee on platelet immunology. *J Thromb Haemost*. 2021;19(6):1585-1588.
77. Nazy I, Sachs UJ, Arnold DM, et al. Recommendations for the clinical and laboratory diagnosis of VITT against COVID-19: communication from the ISTH SSC subcommittee on platelet immunology. *J Thromb Haemost*. 2021;19(6):1585-1588.
78. Kearon C, Akl EA, Ornelas J, et al. Antithrombotic therapy for VTE disease: CHEST guideline and expert panel report. *Chest*. 2016;149(2):315-352.
79. Wijaya I, Andhika R, Huang I. The use of therapeutic-dose anticoagulation and its effect on mortality in patients with COVID-19: a systematic review. *Clin Appl Thromb Hemost*. 2020;26:1076029620960797.
80. Ionescu F, Jaiyesimi I, Petrescu I, et al. Association of anticoagulation dose and survival in hospitalized COVID-19 patients: a retrospective propensity score-weighted analysis. *Eur J Haematol*. 2021;106(2):165-174.
81. Nadkarni GN, Lala A, Bagiella E, et al. Anticoagulation, bleeding, mortality, and pathology in hospitalized patients with COVID-19. *J Am Coll Cardiol*. 2020;76(16):1815-1826.
82. Investigators R-C, Investigators AC-a, Investigators A, et al. Therapeutic anticoagulation with heparin in critically ill patients with covid-19. *N Engl J Med*. 2021;385(9):777-789.
83. Obi AT, Barnes GD, Wakefield TW, et al. Practical diagnosis and treatment of suspected venous thromboembolism during COVID-

- 19 pandemic. *J Vasc Surg Venous Lymphat Disord.* 2020;8(4): 526-534.
84. Gupta A, Sardar P, Cash ME, Milani RV, Lavie CJ. Covid-19 vaccine-induced thrombosis and thrombocytopenia—a commentary on an important and practical clinical dilemma. *Prog Cardiovasc Dis.* 2021; 67:105-107.
  85. Smith CW, Montague SJ, Kardeby C, et al. Anti-platelet drugs block platelet activation by vaccine-induced immune thrombocytopenia and thrombosis patient serum. *Blood.* 2021;138(25):2733-2740.
  86. Long B, Bridwell R, Gottlieb M. Thrombosis with thrombocytopenia syndrome associated with COVID-19 vaccines. *Am J Emerg Med.* 2021;49:58-61.
  87. von Hundelshausen P, Lorenz R, Siess W, Weber C. Vaccine-induced immune thrombotic thrombocytopenia (VITT): targeting pathomechanisms with bruton tyrosine kinase inhibitors. *Thromb Haemost.* 2021;121(11):1395-1399.
  88. Makris M, Pavord S, Lester W, Scully M, Hunt B. Vaccine-induced immune thrombocytopenia and thrombosis (VITT). *Res Pract Thromb Haemost.* 2021;5(5):e12529.
  89. Cattaneo M, Bertinato EM, Birocchi S, et al. *Pulmonary Embolism or Pulmonary Thrombosis in COVID-19? Is the Recommendation to Use High-Dose Heparin for Thromboprophylaxis Justified?* 2020.
  90. NfHaC Excellence. *COVID-19 Rapid Guideline: Managing COVID-19.* National Institute for Health and Care Excellence (NICE); 2021.
  91. Thachil J, Tang N, Gando S, et al. ISTH interim guidance on recognition and management of coagulopathy in COVID-19. *J Thromb Haemost.* 2020;18(5):1023-1026.
  92. Investigators I, Sadeghipour P, Talasaz AH, et al. Effect of intermediate-dose vs standard-dose prophylactic anticoagulation on thrombotic events, extracorporeal membrane oxygenation treatment, or mortality among patients with COVID-19 admitted to the intensive care unit: the INSPIRATION randomized clinical trial. *JAMA.* 2021;325(16):1620-1630.
  93. Al-Samkari H. Finding the optimal thromboprophylaxis dose in patients with COVID-19. *JAMA.* 2021;325(16):1613-1615.
  94. Ramacciotti E, Macedo AS, Biagioni RB, et al. Evidence-based practical guidance for the antithrombotic management in patients with coronavirus disease (COVID-19) in 2020. *Clin Appl Thromb Hemost.* 2020;26:1076029620936350.
  95. Turshudzhyan A. Anticoagulation options for coronavirus disease 2019 (COVID-19)-Induced coagulopathy. *Cureus.* 2020;12(5): e8150.
  96. Spyropoulos AC, Levy JH, Ageno W, et al. Scientific and standardization committee communication: clinical guidance on the diagnosis, prevention, and treatment of venous thromboembolism in hospitalized patients with COVID-19. *J Thromb Haemost.* 2020; 18(8):1859-1865.
  97. Moores LK, Tritschler T, Brosnahan S, et al. Prevention, diagnosis, and treatment of VTE in patients with coronavirus disease 2019: CHEST guideline and expert panel report. *Chest.* 2020;158(3): 1143-1163.
  98. Salih F, Schonborn L, Kohler S, et al. Vaccine-induced thrombocytopenia with severe headache. *N Engl J Med.* 2021;385(22): 2103-2105.
  99. Jefferson T. Real or perceived adverse effects of vaccines and the media—a tale of our times. *Journal of Epidemiology and Community Health.* 2000;54(6):402-403.
  100. Holton A, Weberling B, Clarke CE, Smith MJ. The blame frame: media attribution of culpability about the MMR–autism vaccination scare. *Health Commun.* 2012;27(7):690-701.
  101. Ritvo P, Irvine J, Klar N, et al. A Canadian national survey of attitudes and knowledge regarding preventive vaccines. *J Immune Based Ther Vaccines.* 2003;1(1):3.
  102. Wakefield AJ, Murch SH, Anthony A, et al. RETRACTED: ileal-lymphoid-nodular hyperplasia, nonspecific colitis, and pervasive developmental disorder in children. *Lancet.* 1998;351(9103): 637-641.
  103. Rao TSS, Andrade C. The MMR vaccine and autism: sensation, refutation, retraction, and fraud. *Indian J Psychiatry.* 2011;53(2): 95-96.
  104. Taylor LE, Swerdfeger AL, Eslick GD. Vaccines are not associated with autism: an evidence-based meta-analysis of case-control and cohort studies. *Vaccine.* 2014;32(29):3623-3629.
  105. Greenberg J, Dubé E, Driedger M. Vaccine hesitancy: in search of the risk communication comfort zone. *PLoS Curr.* 2017;9: 0561a011117a011111d011111f019596e024949e018690b.
  106. Puri N, Coomes EA, Haghbayan H, Gunaratne K. Social media and vaccine hesitancy: new updates for the era of COVID-19 and globalized infectious diseases. *Hum Vaccines Immunother.* 2020; 16(11):2586-2593.
  107. Mahase E. Covid-19: WHO says rollout of AstraZeneca vaccine should continue, as Europe divides over safety. *BMJ.* 2021;372:n728.
  108. Sønderskov KM, Dinesen PT, Østergaard SD. Sustained COVID-19 vaccine willingness after safety concerns over the Oxford-AstraZeneca vaccine. *Dan Med J.* 2021;68(5).
  109. Comerford D, Olivarius O, Bell D, et al. *Did Negative News Regarding the Oxford AstraZeneca Vaccine End in Vaccine Hesitancy? A Repeated Cross-Section Event Study from the UK;* 2021.
  110. Brookes G, Harvey K. Peddling a semiotics of fear: a critical examination of scare tactics and commercial strategies in public health promotion. *Soc Semiot.* 2015;25(1):57-80.
  111. Stolow JA, Moses LM, Lederer AM, Carter R. How fear appeal approaches in COVID-19 health communication may be harming the global community. *Health Educ Behav.* 2020;47(4):531-535.

**How to cite this article:** Afshar ZM, Barary M, Babazadeh A, et al. SARS-CoV-2-related and Covid-19 vaccine-induced thromboembolic events: a comparative review. *Rev Med Virol.* 2022;32(4):e2327. <https://doi.org/10.1002/rmv.2327>